2025 American Association for Thoracic Surgery (AATS) Expert Consensus Document: Surgical management of acute myocardial infarction and associated complications

David J. Kaczorowski, MD,[a] Koji Takeda, MD, PhD,[b] Pavan Atluri, MD,[c] Marisa Cevasco, MD, MPH,[c] Rebecca Cogswell, MD,[d] David D'Allesandro, MD,[e] Mani A. Daneshmand, MD,[f] Valluvan Jeevanandam, MD,[g] Navin K. Kapur, MD, FAHA, FACC, FSCAI,[h] Carmelo Milano, MD,[i] Minoru Ono, MD, PhD,[j] Evgenij Potapov, MD,[k] Danny Ramzy, MD, PhD,[l] Scott C. Silvestry, MD,[m] Edward Soltesz, MD,[n] and Nir Uriel, MD, MSc, FACC[o]

ABSTRACT

Background: Complications of acute myocardial infarction (AMI) can result in significant morbidity and mortality. This document reports the findings and recommendations of a multidisciplinary group of experts on the management of patients with complications of AMI, with particular focus on the use of mechanical circulatory support in this context.

Methods: Through the American Association of Thoracic Surgery Clinical Practice Standards Committee, a committee of multidisciplinary experts, including both cardiologists and cardiothoracic surgeons, was established. A list of topics was developed. Committee members were divided into subgroups that developed relevant questions. A systematic literature review was then performed, and the results were synthesized into clinical recommendations. Expert consensus was then established using the Delphi process.

Results: Based on the results of the systematic literature review, as well as the clinical expertise of the committee, clinical recommendations were developed. Each of these recommendations, the strength of each recommendation, and the level or quality of evidence on which the recommendation was based are presented here. Topics addressed include general considerations, revascularization strategies, cardiogenic shock, papillary muscle rupture, postinfarction ventricular septal defect, free wall rupture, arrhythmias, and the use of durable therapies in this context.

Conclusions: AMI may result in cardiogenic shock, malignant arrhythmias, or mechanical complications, each of which is associated with high mortality. Prompt management of these complications, including consideration for mechanical circulatory support, is warranted. (J Thorac Cardiovasc Surg 2025;170:1327-44)

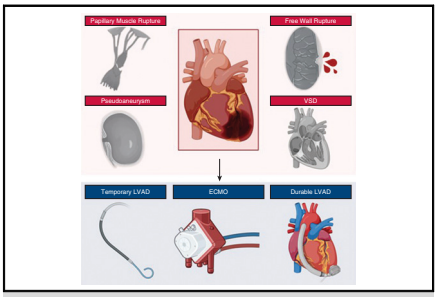

Complications of AMI may necessitate mechanical circulatory support prior to definitive surgical intervention.

CENTRAL MESSAGE

The management of complications of acute myocardial infarction is evolving and should include patient optimization with mechanical support, when necessary, prior to definitive surgical interventions.

PERSPECTIVE

Cardiogenic shock, malignant arrhythmias, and mechanical complications may occur as a result of acute myocardial infarction. These complications are associated with significant morbidity and mortality. Early institution of temporary mechanical support as a bridge to recovery, surgical intervention, or advanced therapy may mitigate adverse outcomes associated with these complications.

ADULT

From the [a]Department of Cardiothoracic Surgery, University of Pittsburgh Medical Center, Pittsburgh, Pa; [b]Department of Surgery, Columbia University Medical Center, New York, NY; [c]Department of Surgery, Hospital of the University of Pennsylvania, Philadelphia, Pa; [d]Cardiovascular Division, University of Minnesota, Minneapolis, Minn; [e]Department of Surgery, Massachusetts General Hospital, Boston, Mass; [f]Department of Surgery, Emory University, Atlanta, Ga; [g]Department of Surgery, University of Chicago Medicine, Chicago, Ill; [h]Division of Cardiology, Tufts Medicine, Boston, Mass; [i]Department of Surgery, Duke University, Durham, NC; [j]Department of Surgery, The University of Tokyo Hospital, Tokyo, Japan; [k]Department of Thoracic and Cardiovascular Surgery, Deutsches Herzzentrum der Charite, Berlin, Germany; [l]Department of Cardiothoracic and Vascular Surgery, UT Health Houston McGovern School of Medicine, Houston, Tex; [m]Department of Surgery, University of Arizona College of Medicine, Tucson, Ariz; [n]Department of Thoracic and Cardiovascular Surgery, Cleveland Clinic, Cleveland, Ohio; and [o]New York Presbyterian-Columbia University Irving Medical Center, New York, NY.

Drs Kaczorowski and Takeda contributed equally as co-first authors.

ADULT

Abbreviations and Acronyms

AATS	= American Association of Thoracic Surgery
ACS	= acute coronary syndrome
AHF	= advanced heart failure
AMI	= acute myocardial infarction
CABG	= coronary artery bypass grafting
COE	= class of recommendation
CPR	= cardiopulmonary resuscitation
CS	= cardiogenic shock
ECMO	= extracorporeal membrane oxygenation
eCPR	= extracorporeal cardiopulmonary resuscitation
J-PVAD	= Japanese Percutaneous Ventricular Assist Device
LOE	= level of evidence
LV	= left ventricular
LVAD	= left ventricular assist device
MCS	= mechanical circulatory support
OHCA	= out-of-hospital cardiac arrest
PCI	= percutaneous coronary intervention
ROSC	= return of spontaneous circulation
STEMI	= ST segment elevation myocardial infarction
TAH	= total artificial heart
VA	= venoarterial

To view the AATS Annual Meeting Webcast, see the URL next to the webcast thumbnail.

Acute myocardial infarction (AMI) remains a significant global health challenge and is the leading cause of cardiogenic shock (CS), a condition characterized by insufficient cardiac output to meet systemic metabolic demands.[1] Despite advancements in managing ST segment elevation myocardial infarction (STEMI) and other types of AMI, the incidence of CS complicating AMI (AMI-CS) remains approximately 7% to 10%, with alarmingly high mortality rates, up to 50%.[2,3]

AMI-CS is a complex syndrome that often leads to end-organ hypoperfusion and triggers a cascade of systemic complications, including lactic acidosis and multiorgan dysfunction.[4] A large infarct and delayed hospital presentation exacerbate these risks, leaving patients vulnerable to mechanical complications such as acute mitral regurgitation, ventricular septal rupture, pseudoaneurysm, and free wall rupture.[5] Although the incidence of these mechanical complications is relatively low, they are associated with significant morbidity, mortality, and extensive hospital resource utilization. Patients with these mechanical complications often present with CS, which may preclude definitive surgical treatments and necessitates a multidisciplinary team approach.[5,6] This team typically includes noninvasive cardiologists, critical care physicians, heart failure and transplant specialists, interventional cardiologists, palliative care specialists, nursing staff, and cardiac surgeons.

To improve outcomes in AMI-CS, the use of mechanical circulatory support (MCS) devices has become increasingly prominent. These devices, when integrated with optimized invasive management protocols, have shown potential in stabilizing hemodynamics and improving outcomes for patients with AMI-CS with early revascularization. Over the past few decades, pivotal trials such as the IABP-SHOCK II Trial, ECLS-SHOCK Trial, and DanGer Shock Trial have explored hypotheses and offered promising advancements in addressing the challenges of AMI-CS.[2,7,8] This trend also has extended to the cardiac surgery community, focusing on managing mechanical complications associated with AMI. There are 2 primary roles for MCS in these scenarios: (1) bridging acutely ill patients with CS to definitive interventions (such as conventional surgeries or heart replacement therapies) and (2) providing hemodynamic support postoperatively to facilitate myocardial and end-organ recovery. Despite numerous studies on the effectiveness of MCS in these settings, there is no universally accepted guideline for its use.

The objective of this expert consensus document from the American Association for Thoracic Surgery (AATS) Clinical Practice Standards Committee is to systematically review the available literature on the use of MCS and provide evidence-based recommendations for its application in AMI-CS and mechanical complications associated with AMI. This document presents 34 recommendations supported by the available evidence. However, owing to the lack of robust data, many recommendations are based on expert consensus opinions. The class of recommendation (COR) and the level of evidence (LOE) are reported according to the recommended terminology in harmonizing guidelines consensus document from the AATS, European

Read at the 105th Annual Meeting of The American Association for Thoracic Surgery, Seattle WA, May 2-5, 2025.
Received for publication Feb 18, 2025; revisions received April 8, 2025; accepted for publication April 8, 2025; available ahead of print May 2, 2025.
Address for reprints: David J. Kaczorowski, MD, Department of Cardiothoracic Surgery, University of Pittsburgh Medical Center, F675 PUH, 200 Lothrop St, Pittsburgh, PA 15224 (E-mail: kaczorowskidj2@upmc.edu).
0022-5223/$36.00
Copyright © 2025 Published by Elsevier Inc. on behalf of The American Association for Thoracic Surgery
https://doi.org/10.1016/j.jtcvs.2025.04.013

Association for Cardio-Thoracic Surgery, European Society of Thoracic Surgeons, and Society of Thoracic Surgeons.[9]

METHODOLOGY

Assembly of an International Writing Group of Experts

This expert consensus document was initiated by the AATS Clinical Practice Standards Committee. The writing group was assembled in accordance with the AATS/Society of Thoracic Surgeons position statement on developing clinical practice documents.[10,11] The group included cardiothoracic surgeons and cardiologists with expertise in the diagnosis and management of mechanical complications of AMI, MCS, CS, and heart failure. Committee meetings were held remotely or with remote options to facilitate attendance of members from diverse geographic locations. Each member of the writing group completed a conflict of interest disclosure statement.

Formulation of Objectives and Questions

Once established, the writing group met to develop a list of topics to address in this report. The final list of topics to was reviewed and approved by the co-chairs and included the management of shock and mechanical complications associated with AMI: papillary muscle rupture, acute mitral regurgitation, ventricular septal defect (VSD), free wall rupture, and refractory arrhythmia. After a list of topics was developed, the group was divided into subgroups. The members of each subgroup developed questions using the PICO format (population/patients/or problem, intervention, comparison, outcome). The questions were reviewed and approved by the entire group, including the co-chairs. Members of each subgroup then conducted a literature review for corresponding questions and synthesized the results of the review into clinical recommendations.

Literature Review and Evidence Synthesis

With the aid of librarians and using systematic review methodology, search strategies aimed to identify studies related to the surgical management of AMI and mechanical complications associated with acute myocardial ischemia. Search areas included such topics as revascularization techniques, MCS options, and others. The searches incorporated keyword and medical subject headings (MeSH) for each concept, which were applied to PubMed searches conducted on August 31, 2023. No limitations on language or publication dates were applied.

After articles of interest were identified, members of the subgroups reviewed relevant abstracts and selected articles for full-text review. The selected articles were reviewed by subgroup members, and information from relevant articles was incorporated into data-based recommendations. Members of each subgroup prepared statements reflecting these recommendations and assigned a level of quality of evidence and a level of recommendation according to previously described methods (Figure 1).[10-13]

Development of Expert Consensus

Expert consensus was established using the Delphi process. Specifically, surveys were created that contained the evidence-based statements developed by the subgroups. The surveys were circulated to all committee members. Each member graded each statement using a 5-point Likert scale in which 1 = strongly disagree; 2 = disagree; 3 = neutral; 4 = agree; 5 = strongly agree. A minimum response rate of 80% was required for each question. A minimum of 75% agreement ("agree" or "strongly agree") was defined as "consensus" for each recommendation. Statements were reviewed by committee members and revised as agreed upon. If consensus was not achieved, statements were subject to revision by the committee. Revised statements were then subjected to an additional round of grading via survey.

Section 1: General Considerations in Patients With Acute Myocardial Ischemia

Statement 1: Temporary MCS (tMCS) can be useful in the management complications of AMI, which may include CS, VSD, papillary muscle/free wall rupture, and others. (CoR: IIa, LoE: B-NR)

AMI can lead to serious complications, including CS and mechanical issues such as VSD, acute mitral regurgitation due to papillary muscle rupture, and free wall rupture, all of which often require surgical intervention. These complications can quickly result in pump failure, hemodynamic instability, and end-organ failure, which may disqualify patients from surgery or significantly increase morbidity and mortality after such procedures.[5,6]

tMCS has emerged as a vital strategy for managing complications associated with AMI. Contemporary devices such as microaxial flow pumps and extracorporeal membrane oxygenation (ECMO) machines can enhance cardiac output and improve hemodynamics, allowing for ventricular unloading and better perfusion of end organs. When combined with appropriate medical support, tMCS can provide a stabilization phase before surgical interventions, potentially improving patient outcomes.[7,8] Furthermore, tMCS can facilitate the recovery of myocardial and end-organ function by delivering stronger hemodynamic support compared to inotropes and vasoactive medications following surgery.

Statement 2: A multidisciplinary approach to evaluation and management of patients with complications of AMI should be considered. (CoR: I, LoE: C-EO)

Diagnosis and management of patients with complications of AMI may be challenging, as these patients frequently suffer from CS. Management of patients with complications of AMI may involve delivery of care from physicians and health care providers with disparate and complementary skill sets. Cardiothoracic surgeons, interventional cardiologists, heart failure cardiologists, critical care physicians, anesthesiologists, and others may participate in the care of patients suffering from complications of AMI and other patients with CS.[14-16] Emerging evidence suggests that standardization of care and the use of a team-based multidisciplinary approach result in improved outcomes and cost-effective care for patients with CS in the setting of AMI.[17-20]

Statement 3: A comprehensive approach to the care of patients with complications of AMI is recommended, including early medical therapy and consideration of tMCS, followed by surgical intervention when indicated and after stabilization and optimization. (CoR: I, LoE: C-EO)

Patients with complications from AMI continue to experience high morbidity and mortality rates. Given the high acuity of these patients, it is crucial for clinicians to recognize the underlying pathophysiology early, establish a timely diagnosis, and initiate medical therapy tailored to each patient's needs. This therapy should focus on such issues as hemodynamic stability and the balance between myocardial oxygen supply and demand.[2-4]

For patients who develop CS and end-organ malperfusion, the use of tMCS can be considered to provide enough hemodynamic support, stabilize the patient, and enhance end-organ perfusion, thereby improving their candidacy for surgical intervention. Once the patient is adequately stabilized and optimized through tMCS, definitive surgical intervention should be pursued without delay.[5,6]

Section 2: Revascularization Strategies

Statement 1: In high-risk patients with acute coronary syndrome (ACS) requiring either percutaneous or surgical revascularization, a heart team approach is recommended. (CoR: I, LoE: C-EO)

There are 3 primary treatment pathways for coronary artery disease: medical management, percutaneous coronary intervention (PCI) by an interventional cardiologist, or coronary artery bypass grafting (CABG) by a cardiac surgeon.[21] Patients presenting with ACS and CS should be counseled that they are at risk for high morbidity and mortality and their care is best managed by a multidisciplinary team that includes the cardiologist,

ADULT

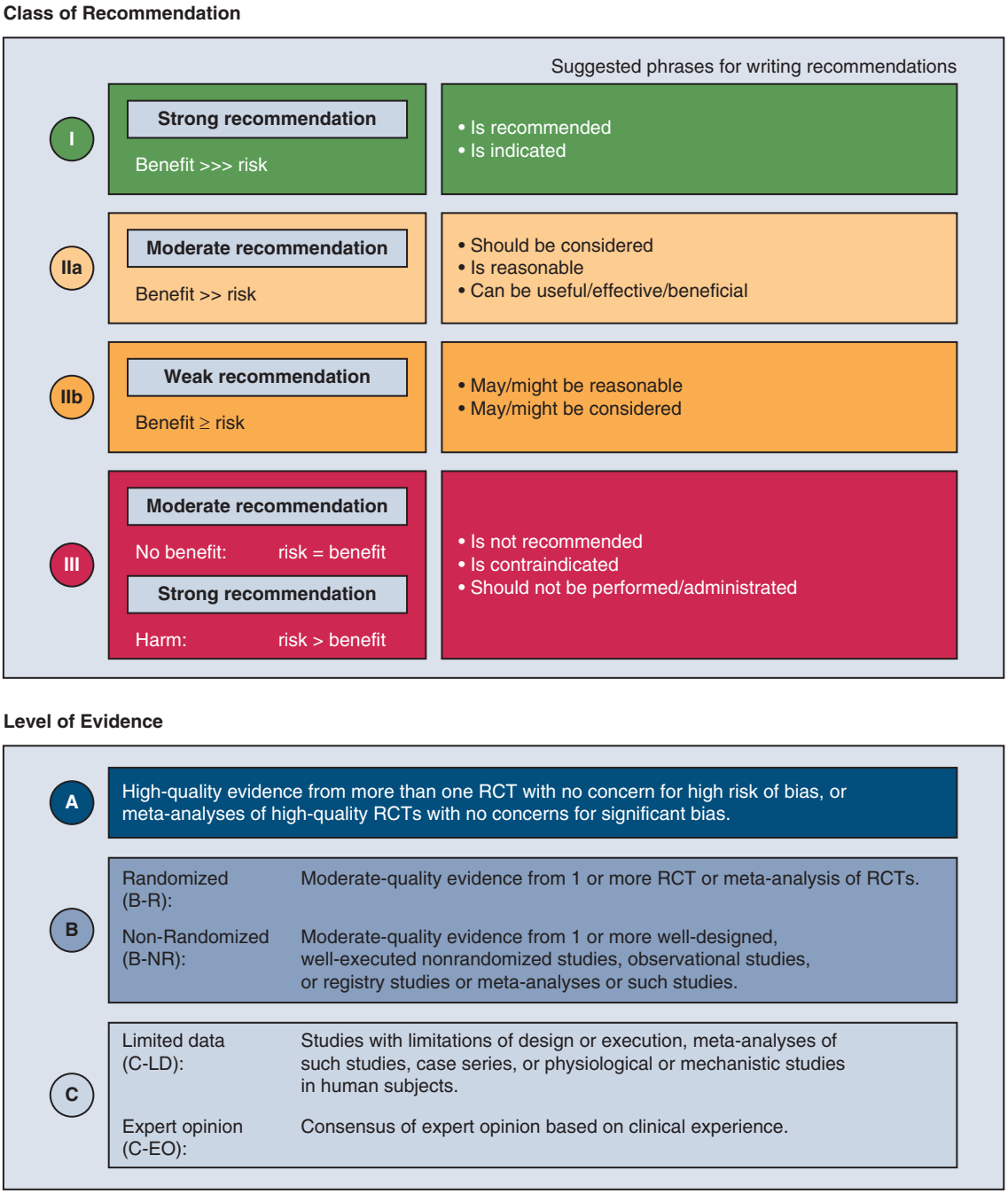

FIGURE 1. Adopted definitions of classes of recommendation and levels of evidence. *RCT*, Randomized controlled trial; *AATS*, American Association of Thoracic Surgery; *EACTS*, European Association for Cardio-Thoracic Surgery; *ESTS*, European Society of Thoracic Surgeons; *STS*, Society of Thoracic Surgeons. From Milojevic M, Freementle N, Hayanga JWA, et al. *J Thorac Cardiovasc Surg*. 2025;169(1):170-185.

interventionalist, and cardiac surgeon.[22] The outlook for patients who are treated promptly is good, but those with severe disease may suffer from high morbidity and early mortality.

Increasing evidence is demonstrating that patients benefit when cardiologists and surgeons work in a collaborative atmosphere and have impromptu discussions on how best to manage specific patients. Many centers have instituted a multidisciplinary heart team that discusses and collaboratively determines the best evaluation and treatment modality based on available data. Such heart teams use combined decision making to determine the best treatment strategy for complex patients with coronary artery disease.[22]

There remains wide variability in the management of coronary artery disease and ACS, raising concerns about inappropriate revascularization. In some reports, PCI was used in more than 70% of cases. Many of these cases were in complex lesions, including 2- or 3-vessel coronary artery disease, left main coronary artery disease, and chronic total occlusions, in which some studies have shown better outcomes with CABG.[22,23] The 2021 American College of Cardiology/American Heart Association/

Statements	Section General considerations in acute ischemic emergencies	CoR	LoE	% consensus
1.1	Temporary MCS can be useful in the management complications of AMI which may include CS, VSD, papillary muscle/free wall rupture, and others.	IIa	B-NR	100%
1.2	A multidisciplinary approach to evaluation and management of patients with complications of AMI should be considered.	I	C-EO	100%
1.3	A comprehensive approach to the care of patients with complications of AMI is recommended, including early medical therapy and consideration of tMCS followed by surgical intervention when indicated and after stabilization and optimization.	I	C-EO	100%

Society for Cardiovascular Angiography and Interventions Guideline states that a heart team approach is recommended for patients with significant left main coronary artery disease, complex coronary anatomy, intermediate or high SYNTAX scores, chronic total occlusions, multivessel disease, and disease at major bifurcations.[23] Furthermore, more recent data has shown that medical management may be equivalent to an invasive strategy in stable ischemic coronary disease.[24] The heart team may be able to help delineate which patients will benefit from optimal medical management versus PCI or CABG.

Statement 2: In high-risk patients undergoing PCI or CABG, particularly those presenting with CS, initial treatment with tMCS is reasonable. (CoR: IIa, LoE: B-NR)

High-risk revascularization can be defined by anatomic, pathophysiologic, technical, and demographic features. For both PCI and CABG, high-risk patient features include acute or chronic heart failure, reduced systolic function or left ventricular dilatation, ACS, and such comorbidities as diabetes, peripheral vascular disease, and acute or chronic kidney disease. For PCI specifically, interventions on multiple coronary target lesions; the need for plaque modification with intracoronary lithotripsy, rotational atherectomy, or high-pressure balloon dilation; and surgical turndown are associated with a higher risk of procedural or clinical complications. The PROTECT II randomized clinical trial failed to show a clear benefit of tMCS-supported coronary intervention in a broad population of patients but identified that patients with the aforementioned risk factors derive a statistically significant benefit from the use of tMCS during revascularization.[25] These findings have been supported by more recent retrospective and prospective studies.[26,27] More recently, a post hoc analysis of the Japanese Percutaneous Ventricular Assist Device (J-PVAD) registry demonstrated that patients with STEMI who underwent unloading with a microaxial temporary left ventricular assist device (LVAD) prior to coronary reperfusion had a statistically significantly higher 30-day survival compared to those with postperfusion unloading when the time from onset to unloading was ≥6 hours. Furthermore, a multivariable analysis identified preperfusion use of a microaxial temporary LVAD as an independent predictor of survival in those with an onset to unloading duration of ≥6 hours.[28] For high-risk CABG, the use of tMCS before, during, or after surgical revascularization may allow for presurgical hemodynamic optimization and further mitigate the risk of low cardiac output after surgery and improve survival to discharge.[29,30] Axillary options for tMCS after surgery enable early ambulation. Additional prospective studies are required to test the clinical utility of tMCS in the perioperative period with CABG. Emerging tMCS options with smaller-bore vascular access and high-flow capacity may further reduce the risk of complications and lead to increased use of tMCS to support high-risk revascularization.

Statement 3: In patients presenting with ACS with prior cardiac arrest and return of spontaneous circulation (ROSC), stabilization with tMCS can be considered. (CoR: IIa, LoE: C-LD)

The use of tMCS for patients with ACS complicated by cardiac arrest is growing exponentially. Recently, the American Heart Association resuscitation guidelines issued a class 2A recommendation for the use of venoarterial (VA)-ECMO for out-of-hospital cardiac arrest as part of an ECMO-assisted cardiopulmonary resuscitation (CPR) program.[31] The recommendation was driven primarily by the ARREST Trial, which was terminated early owing to the clear efficacy of VA-ECMO–assisted CPR in the setting of ACS and cardiac arrest.[32] The American Heart Association/American College of Cardiology consensus statement on ECMO-assisted CPR provides guidance on patient selection for ECMO-assisted CPR in the setting of ACS. The findings of the ARREST Trial are balanced by the results of the ECLS-Shock trial, which demonstrated that the routine use of VA-ECMO for ACS complicated by CS did not improve survival compared to standard of care.[7] Two other large randomized trials also failed to show a benefit of ECMO-assisted CPR compared to conventional CPR.[33,34]

Use of the Impella for STEMI complicated by CS was recently tested in the Danish-German (DanGer) shock trial, which demonstrated improved survival among patients with STEMI and CS randomized to an Impella CP before PCI compared to PCI alone. In this study, approximately 20% of subjects were resuscitated before randomization.[8] Future studies are needed to further test the utility of tMCS in the setting of ACS complicated by cardiac arrest with ROSC.

Statement 4: In patients with AMI with ongoing ischemia whose anatomy is not amenable to PCI, CABG with or without tMCS should be considered, and transfer CABG with or without tMCS should be considered, and urgent transfer to a tertiary center should be considered. (CoR: IIa, LoE: C-LD)

Patients presenting with an AMI may have anatomy unfavorable for PCI or may be intolerant of the requisite antiplatelet therapy mandated for PCI with stenting. These patients should be considered for surgical intervention or transfer to a tertiary center that may have more experience with complex PCI.[35] However, tMCS should be considered to stabilize the patient prior to transfer or urgent surgery. The recent DanGer shock trial showed that implantation of a microaxial flow pump may increase survival at 6 months among patients with STEMI, particularly those complicated by CS.[8] This study, the first randomized clinical trial to demonstrate a benefit of a tMCS device for patients with AMI and CS, concluded that patients have a 12.8% absolute risk reduction in mortality with the use of a tMCS device. It is important to note, however, that these devices have a complication profile that includes bleeding, limb ischemia, and the need for renal replacement therapy.[8] In another recent retrospective study using data from the J-PVAD registry, patients with AMI complicated by CS were supported with a microaxial temporary LVAD and divided into 2 groups based on the method of coronary revascularization. Compared to patients in the PCI group, patients who underwent CABG had significantly lower 30- and 90- day mortality. Although this study design might have been subject to selection bias, the authors concluded that CABG may be a viable option for patients with AMI-complicated CS who are supported by a microaxial temporary LVAD.[36]

Additionally, several studies have demonstrated that patients admitted to tertiary care hospitals for STEMI management have higher survival rates, independent of the difference in comorbidity burden. Higher-volume centers may have greater capability for rescuing patients in AMI shock.[37,38]

ADULT

Statements	Section Revascularization strategies	CoR	LoE	% consensus
2.1	In high-risk patients with ACS requiring either percutaneous or surgical revascularization, a heart team approach is recommended.	I	C-EO	92%
2.2	In high-risk patients undergoing PCI or CABG, particularly those presenting with CS, initial treatment with tMCS is reasonable.	IIa	B-NR	83%
2.3	In patients presenting with ACS, with prior cardiac arrest and ROSC, stabilization with tMCS can be considered.	IIa	C-LD	92%
2.4	In patients with AMI with ongoing ischemia whose anatomy is not amenable to PCI, CABG with or without tMCS, or tMCS with urgent transfer to tertiary center should be considered	IIa	C-LD	100%

Section 3: CS after AMI

Statement 1: tMCS should be initiated before severe organ dysfunction occurs. (CoR: I, LoE: B-NR)

Organ-specific markers of injury can indicate evidence of impaired forward flow and the effects of venous congestion and microcirculatory derangements. Although it is impossible to predict the reversibility of end-organ damage in the acute setting, markers of organ injury provide a useful gauge of the severity of CS. Multiple retrospective studies have demonstrated a direct relationship between organ failure and the severity of shock.[39-42] Current clinical practice advocates for using tMCS to improve organ perfusion and facilitate venous decongestion. As such, laboratory markers of organ injury, if available, should be used to assess the severity of shock. In the acute setting, patients with clinically evident CS should be considered for tMCS for intervention before the evolution of end-organ damage. Although laboratory markers of end-organ function may worsen within hours after shock onset, clinical markers like anuria or disorders in mentation, as well as signs of metabolic disorders, are immediately evident.[43]

Statement 2: Escalating vasoactive inotropic agents may be considered as a trigger for tMCS. (CoR: IIb, LoE: B-R)

Severe or rapidly deteriorating CS often is first recognized with an increasing requirement for vasoactive medications. Mortality increases proportionally with the number of vasoactive drips required to maintain adequate perfusion pressure. One potentially useful objective measure of cumulative vasoactive and inotropic support is the vasoactive inotrope score, calculated as: dopamine dose (μg/kg/min) + dobutamine dose (μg/kg/min) + 100 × epinephrine dose (μg/kg/min) + 10 × milrinone dose (μg/kg/min) + 10,000 × vasopressin dose (unit/kg/min) + 100 × norepinephrine dose (μg/kg/min).[44,45] The Society of Cardiovascular Angiography and Interventions classification enables very comprehensive assessment of severity of CS.[43,46,47]

Statement 3: Clinical evidence of tissue hypoperfusion in the face of increasing serum lactate is recommended as a trigger for tMCS. (CoR: I, LoE: B-R)

Serum lactate levels have been shown to correlate with the probability of mortality for patients in CS without tMCS intervention.[48-51] Based on several clinical trial criteria and society guidelines, an elevated or rising serum lactate level should be considered consistent with a diagnosis of CS.[2] Serum lactate has also been evaluated for its utility in prognosticating a patient's course while on tMCS.[52-56] It is evident that a rising serum lactate increases the risk of mortality from shock, and expeditious cannulation for tMCS would be indicated to prevent a worsening risk of mortality. Two retrospective studies found that lactate >15 mmol/L corresponded with 100% mortality, although few patients presented with this high lactate level.[55,57] However, the variability in published data precludes defining an absolute lactate threshold level beyond which the use of tMCS is futile. This variability implies that serum lactate levels will fluctuate in shock and creates an interplay between metabolic derangement and organ injury. Although a single serum lactate measurement is insufficient for reliable outcome prediction, worsening lactic acidosis should serve as a trigger for the initiation of tMCS.

Statement 4: In patients with AMI complicated by witnessed out-of-hospital cardiac arrest, immediate bystander CPR, and with a shockable rhythm, consider extracorporeal CPR (eCPR) within 60 minutes of arrest as an adjunct treatment. (CoR: IIa, LoR: B-NR)

Outcomes differ significantly based on the location of the cardiac arrest. In-hospital cardiac arrest (IHCA) is associated with better survival than out-of-hospital cardiac arrest (OHCA).[58,59] Careful decision making is required to determine the duration of CPR at which cannulation should be considered and beyond which would be futile care. In the Prague OHCA randomized trial, eCPR was associated with improved 30-day survival but not with improved 6-month survival.[33] However, a subsequent analysis found a survival benefit with eCPR for patients who did not achieve ROSC by hospital arrival.[60]

Statement 5: In patients with AMI complicated by in hospital cardiac arrest, consider eCPR for patients with a shockable rhythm who do not experience ROSC for >10 minutes but <60 minutes and who have no obvious contraindications for ECMO. (CoR: IIa, LoE: B-NR)

Outcomes differ significantly based on the location of the cardiac arrest, with better survival in cases of IHCA compared to OHCA.[58,59] Careful decision making is necessary to determine the duration of CPR at which cannulation should be considered and beyond which would be futile care. A meta-analysis of 4 randomized controlled trials noted improved survival using an eCPR strategy versus conventional CPR.[61] This effect was most significant among patients initially presenting with a shockable rhythm.[61]

Statement 6: Patients with AMI complicated by CS are recommended to receive microaxial flow pump that provides left ventricular (LV) unloading prior to revascularization. (CoR: I, LoE: B-R)

ACS is a common cause of acute cardiogenic shock. Recent studies have supported the benefits of tMCS in conjunction with coronary revascularization. A meta-analysis of 11 observational studies found improved survival with the initiation of a microaxial flow pump before PCI.[62] As discussed above, a recent study using the J-PVAD registry demonstrated that patients with STEMI who underwent unloading with a microaxial temporary LVAD prior to coronary reperfusion had a statistically significantly higher 30-day survival compared to those with postperfusion unloading when the time from onset to unloading was ≥6 hours.[28] Observational studies also have demonstrated the benefits of cannulation for ECMO before PCI or surgical revascularization.[63-68]

Statement 7: In patients supported with venoarterial ECMO, LV unloading should be considered. (CoR: IIa, LoE: B-NR)

The use of an intra-aortic balloon pump (IABP) is not beneficial for patients with CS caused by AMI.[69,70] There are conflicting data on the impact of tMCS including ECMO use on outcomes in patients with increased inotrope requirements despite a direct association of escalating doses with

mortality.[7,57,71,72] Although the recently reported DanGer trial showed a clear survival benefit with microaxial flow pump providing support of up to 3.5 L/minute in those patients, isolated VA-ECMO is not beneficial in patients with CS caused by AMI, which may be related to increased LV afterload.[7,8] Recent data suggest, however, that the use of ECMO along with an IABP in patients with CS may result in superior outcomes compared to the use of ECMO alone and perhaps ECMO and a microaxial LVAD.[73,74]

Statement 8: The initiation of tMCS is not recommended in patients with life-limiting systemic disease of <1 year, catastrophic neurologic injury, unwitnessed arrest, and previously documented patient or family wishes. (CoR: III, LoE: C-EO)

Multiple relative contraindications to the use of tMCS have been suggested. Patients with evidence of catastrophic neurologic injury or severe noncardiac disease limiting life expectancy will not benefit from the tMCS. Other factors, such as extended advanced cardiac life support resuscitation time or severe metabolic derangement, indicate little likelihood of patient and/or organ recovery. Finally, documenting patient wishes to avoid invasive life-sustaining measures should be respected in recognition of patient autonomy.

Section 4: Management of Papillary Muscle Rupture and Acute Mitral Regurgitation After AMI

Statement 1: For patients with papillary muscle rupture due to AMI in CS, hemodynamic stabilization with tMCS, including active LV unloading, should be considered as soon as shock is recognized. (CoR: IIa, LoE: B-NR)

Early reperfusion strategies, including percutaneous coronary revascularization, have significantly decreased the incidence of mechanical complications of AMI, including papillary muscle rupture, with an incidence <0.1%.[6] The incidence of these complications has decreased over time with the advent of timely PCI for rapid restoration of myocardial perfusion. Analysis of 233 patients with post-AMI mechanical complications from a multi-institutional database in East Japan demonstrated a decreasing incidence of mechanical complications from 3.7% to 1.9% over a 21-year period.[75] Unfortunately, the mortality associated with acute papillary muscle rupture remains very high, especially without early diagnosis and surgery. Early diagnosis of this fatal complication is critical before the onset of CS. Surgery in the presence of CS is associated with a very high mortality.[76] Rapid progression of CS prior to surgery has been identified as an independent predictor of mortality with surgery for papillary muscle rupture.[77] With a delayed presentation and recognition of acute papillary muscle rupture, hemodynamic stabilization with tMCS can be beneficial in reversing shock, preserving end-organ function, and decreasing mortality associated with mitral valve surgery. Strong consideration for restoration of hemodynamic stability and ventricular unloading with tMCS is critical to allow for recovery of a patient with acute papillary muscle rupture.[78]

The use of a microaxial flow pump has demonstrated efficacy in hemodynamic stabilization and allowing percutaneous revascularization prior to surgical intervention.[79] This therapy has the benefit of both restoring cardiac output and unloading the left ventricle. ECMO can be particularly effective in providing stabilization in the presence of circulatory collapse prior to surgical intervention for papillary muscle rupture.[80] Historically, early insertion of an IABP has been associated with a markedly significant decrease in 30-day mortality in patients with shock (61% vs 100%; $P = .04$), although this benefit was not evident in the absence of shock (20% vs 27%; $P = .7$).[77,81]

Statement 2: For patients with papillary muscle rupture due to AMI without CS, emergency mitral valve surgery is recommended for appropriate candidates. (CoR: I, LoE: B-NR)

Papillary muscle rupture is a rare but fatal complication of AMI if untreated.[82] This unfortunate complication is most pronounced in patients with large infarctions or delayed revascularization.[5] Multimodality assessment and stabilization with a combination of medical and mechanical support may be required prior to proceeding with surgery. For patients without prohibitive comorbidities, emergency mitral valve surgery is required for definitive correction of the mechanical complication. Although surgery remains the definitive therapy, the timing of intervention (with or without stabilization using MCS) remains unclear, given the paucity of data on this rare but fatal complication.[6] Mitral valve surgery for acute post-AMI papillary muscle rupture is associated with very high rates of morbidity and mortality, as well as longer hospital length of stay and utilization.[5,76] While intraoperative mortality in the modern era is low (4.5%), in-hospital mortality remains high.[83] Even with these high mortality rates, the lack of an effective medical or percutaneous therapy makes surgical correction of acute mitral regurgitation from papillary muscle rupture the cornerstone

Statement	Section CS after AMI	CoR	LoE	% consensus
3.1	tMCS should be initiated before severe organ dysfunction occurs.	I	B-NR	92%
3.2	Escalating vasoactive inotropic agents may be considered as a trigger for tMCS.	IIb	B-R	100%
3.3	Clinical evidence of tissue hypoperfusion in the face of increasing lactate is recommended as a trigger for tMCS.	I	B-R	100%
3.4	In patients with AMI complicated by witnessed OHCA and immediate bystander CPR, and with a shockable rhythm, consider eCPR within 60 min of arrest as an adjunct treatment.	IIa	B-NR	92%
3.5	In patients with ACI complicated by IHCA, consider eCPR for patients with a shockable rhythm who do not experience ROSC >10 min but <60 min and have no obvious contraindications to ECMO.	IIa	B-NR	100%
3.6	Patients with AMI complicated by CS are recommended to receive a microaxial flow pump that provides LV unloading prior to revascularization.	I	B-R	91%
3.7	In patients supported with VA-ECMO, LV unloading should be considered.	IIa	B-NR	85%
3.8	The initiation of tMCS is not recommended in patients with life-limiting systemic disease of <1 y, catastrophic neurologic injury, unwitnessed arrest, and previously documented patient or family wishes.	III	C-EO	100%

ADULT

of therapy.[84] Unperformed surgical correction of mitral regurgitation remains a nearly fatal condition (hazard ratio >5.1).[77] Although many surgeons have attempted mitral valve repair with papillary muscle reimplantation, this approach has been associated with a very high rate of recurrent mitral regurgitation.

Mitral valve replacement remains the most durable option for these critically ill patients. Early detection with echocardiography is vital to minimizing complications and mortality.[75] Advanced age, inferior wall MI, CS, and cardiac arrest are all independent predictors or mortality with mitral surgery for acute papillary muscle rupture.[85,86] While early mortality rates are high, the mid- and long-term outcomes in those who survive is an encouraging 75% at 1 year, 65% at 5 years, and 32% at 10 years.[87]

Statement 3: In patients at prohibitive risk for mitral valve surgery, transcatheter edge-to-edge repair (TEER) may be considered by the heart team in selected cases. (CoR: IIb, LoE: C-LD)

Patients at prohibitive risk for surgery for acute papillary muscle rupture have limited viable options for therapeutic, life-saving interventions. Percutaneous therapies exist for correction of mitral regurgitation, but these remain experimental or have not yet been studied in this complex subset of patients. Notably, TEER remains one particular off-label therapy. Anecdotal reports demonstrate the potential for TEER in managing patients with acute post-AMI mitral regurgitation. In a highly selected report from 3 centers including 8 patients, a 30-day mortality rate of 9% was demonstrated. Seventy-five percent of these cases required MCS.[88] Similar isolated case reports and series have demonstrated success in selected circumstances for patients deemed at prohibitive risk for surgery.[89,90] Further investigation of the efficacy of this therapy in this complex patient cohort, as well as a detailed understanding or anatomic predictors of success, are needed to determine the potential of TEER in acute papillary muscle rupture. In the meantime, TEER should be considered for those patients with no surgical options.

Section 5: Management of Postinfarction VSD

Statement 1: Early institution of tMCS can be useful to stabilize hemodynamics and reverse CS from a postinfarction VSD prior to surgical repair. (CoR: IIa, LoE: C-LD)

Acute postinfarction VSD is associated with high mortality and morbidity owing to a combination of CS, pulmonary congestion, and end-organ dysfunction due to systemic hypoperfusion. Surgically untreated patients cannot survive, but acute deterioration may preclude the surgical repair. Early institution of tMCS can be useful to stabilize hemodynamics and reverse CS from the VSD prior to surgical repair.[91] Historically, 2 types of tMCS devices, such as IABP and ECMO, have been used to support the hemodynamically unstable patients. IABP decreases systolic pressure leading to increased systemic flow and reduction of the left-to-right shunt.[92] ECMO increases systemic perfusion and thereby restores end-organ perfusion but may reduce the left-to-right shunt by elevating the left ventricular afterload.[93] Recently, microaxial flow pumps were introduced to unload the left ventricle in CS patients caused by AMI. The hemodynamic effects of microaxial flow pumps have been well described in the setting of VSD. A microaxial flow pump can directly unload the left ventricle to increase systemic blood flow and significantly reduce shunt through the VSD. Pulmonary edema can be avoided or reversed due to reduction of the pulmonary capillary wedge pressure.[94]

Statement 2: A microaxial flow pump may be considered for LV unloading and hemodynamic stabilization prior to post-AMI VSD repair. (CoR: IIb, LoE: C-LD)

Early institution of tMCS is mandatory to stabilize hemodynamic conditions, reverse CS, and prevent end-organ dysfunction. Among several other devices, a microaxial flow pump is the most useful and effective by avoiding end-organ dysfunction due to increased systemic forward flow and protecting the lung from severe congestion due to strong unloading of the left ventricle and a reduced left-to-right shunt.[95] Several successful surgical experiences for VSD with early insertion of a microaxial flow pump have been reported[96,97]; however, the potential benefit of direct LV unloading could be counterbalanced by the possible adverse effects associated with the use of a microaxial flow pump, such as hemolysis, bleeding, and infection. There is also the risk of development of a right-to-left shunt or ingestion of myocardial fragments.[98]

Statement 3: Surgical repair of post-AMI VSD should be performed following hemodynamic stabilization. (CoR: I, LoE: B-NR)

Surgical repair of VSD should be performed after hemodynamic stabilization is achieved. A microaxial flow pump with or without ECMO may be the most reliable support strategy for an acute presentation of VSD. Some patients may be stabilized by increasing forward output and alleviating pulmonary congestion and oxygenation, but other patients might not respond as expected. In the latter case, deferring repair might not be recommended.[99] Delaying a repair surgery for a week or longer may make surgery easier and safer owing to healing of the infarcted myocardial tissue surrounding the VSD[97,99,100]; however, early repair after stabilization with a microaxial flow pump also has been reported.[101]

Section 6: Management of Ventricular Free Wall Rupture

Statement 1: Patients with acute free wall rupture with shock physiology should undergo emergent surgical repair. (CoR: I, LoE: C-EO)

Despite decreasing in incidence, LV free wall rupture remains one of the most lethal complications of AMI,[86] with mortality ranging from 30% up to 90% in some series.[102-104] Surgical repair is the standard of care for free wall rupture; however, the optimal timing and therapeutic strategy remain controversial.[105] Early diagnosis and appropriate management are crucial for facilitating better clinical outcomes. The topic of preoperative optimization is a valid contemplation; however, a meta-analysis of 11 trials found no protective effect of either preoperative or postoperative IABP support on operative mortality.[106]

If untreated, CS leads to cardiac tamponade and cardiocirculatory collapse. Furthermore, the friable tissue surrounding the infarct zone can

Statements	Section Papillary muscle rupture/acute MR	CoR	LoE	% consensus
4.1	For patients with papillary muscle rupture due to AMI in CS, hemodynamic stabilization with tMCS, including active LV unloading, should be considered as soon as shock is recognized.	IIa	B-NR	100%
4.2	For patients with papillary muscle rupture due to AMI without CS, emergency mitral valve surgery is recommended for appropriate candidates.	I	B-NR	100%
4.3	In patients at prohibitive risk for mitral valve surgery, TEER may be considered by the heart team in selected cases.	IIb	C-LD	77%

Statements	Section VSD	CoR	LoE	% consensus
5.1	Early institution of tMCS can be useful to stabilize hemodynamics and reverse CS from a postinfarction VSD prior to surgical repair.	IIa	C-LD	100%
5.2	A microaxial flow pump device may be considered for LV unloading and hemodynamic stabilization prior to post-AMI VSD.	IIb	C-LD	92%
5.3	Surgical repair of post-AMI VSD should be performed following hemodynamic stabilization.	I	B-NR	100%

rapidly evolve into a large and surgically unrepairable rupture, which would drastically increase operative mortality. Intervening prior to cardiopulmonary collapse is the only action that can reduce mortality. In the same meta-analysis, the only risk factor for increased mortality was preoperative use of ECMO for cardiopulmonary collapse.[106] Although the exact timing of a curative intervention is not known, emerging surgical repair with or without postoperative MCS for patients presenting in shock is the optimal strategy for reducing mortality.

Statement 2: Patients with chronic contained free wall rupture may be managed nonoperatively initially but should be monitored with invasive hemodynamic monitoring and frequent echocardiograms. (CoR: IIb, LoE: C-EO)

LV free wall rupture presenting acutely has an extremely high rate of mortality, especially if undetected. However, there is a paucity of data on how to manage chronic pathology, especially when detected as an incidental finding. Also known as a LV pseudoaneurysm, it is not a surgical emergency like its predecessor acute free wall rupture but nonetheless is associated with a 30% to 45% risk of rupture.[107] Once ruptured, the mortality risk mirrors that of an acute free wall rupture. However, when an LV pseudoaneurysm is managed electively, the mortality rate drops to approximately 10%, supporting timely surgical intervention the optimal approach. Thus, it is appropriate to monitor these patients with frequent echocardiographic imaging and invasive hemodynamic monitoring. Cardiac magnetic resonance imaging can be used in stable patients to further define the anatomy and to obtain virtual postrepair left volume parameters. There is some evidence suggesting that patients who remain hemodynamically stable can be managed conservatively.

A small study found no mortality difference at a 5-year follow-up with medical management[108]; however, a larger study of 52 patients found a higher mortality rate in patients managed medically compared to those managed surgically (60% vs 31%). Therefore, it is sensible to take into account the patient's hemodynamic and functional status as well as the comorbidity profile when choosing a surgical management strategy.[109] For patients with chronic free wall rupture who present with symptoms, invasive hemodynamic monitoring and frequent echocardiography is the optimal treatment strategy, whereas urgent surgery is the first-line choice for rupture, with elective surgery for rupture discovered incidentally and asymptomatic patients.

Statement 3: Patients with subacute/chronic free wall rupture with CS may be supported with tMCS prior to surgical intervention. (CoR: IIb, LoE: C-EO)

The use of tMCS in subacute/chronic free wall rupture has been far less studied. Approximately 30% of free wall ruptures present subacutely, and 94% of those present with hypotension.[110] As described in the previous section, patients with subacute and chronic dissections have lower rates of free rupture and tamponade compared to patients with acute rupture, with a significantly lower mortality rate when treated nonurgently.[107] Thus, it is reasonable to consider preoperative hemodynamic optimization. Analyses of the preoperative use of IABP have not shown any protective effect on operative mortality.[111-114] A multicenter study of clinical risk factors affecting in-hospital mortality in patients with mechanical complications following AMI found that preoperative renal dysfunction or CS was associated with a high hazard ratio for mortality after repair.[75] Hence, these high-risk patients should be considered for tMCS as opposed to IABP support. The preoperative goal is to optimize cardiopulmonary, renal, and metabolic parameters to reduce operative mortality and enhance postoperative recovery. Although no study has examined the ideal device to use in this free wall rupture subpopulation, VA-ECMO and atrial sourcing tMCS for subacute ruptures and avoidance of transaortic devices are recommended. In cases of chronic rupture, all forms of tMCS can be considered, and the choice of device should depend on the patient's hemodynamic needs and the center's expertise.

Statement 4: Percutaneous pericardial drainage is not recommended in patients with free wall rupture and pericardial tamponade. (CoR: III, LoE: C-EO)

Patients with post-AMI complications can present quite dramatically, ranging from hemodynamic compromise to cardiac arrest. Patients with free wall rupture who survive the initial event often present with hypotension or CS. The management of AMI shock differs between patients without free wall rupture and those with rupture, as does the management of cardiac tamponade. Thus, it is important to distinguish pericardial effusion/tamponade from free wall rupture. This determination is critical, as percutaneous pericardiocentesis in patients with free wall rupture is not only ineffective, but harmful; for example, in the SHOCK trial, pericardiocentesis was associated with 50% mortality.[115] Stabilizing the patient and either avoiding or delaying surgery is not a viable strategy and will result in patient harm.

Statement 5: tMCS, such as with a microaxial flow pump or ECMO, may be beneficial for patients with free wall rupture who develop postoperative CS. (CoR: IIb, LoE: B-NR)

The gold standard for free wall rupture is surgical repair; however, postoperative heart failure or CS can develop. Along with the extent of injury, early recognition and management are paramount for optimal outcomes. The leading causes of death after free wall rupture repair are cardiac arrest and CS. The initiation of tMCS in patients with post-AMI free wall rupture may provide hemodynamic stabilization and has the potential to reverse an otherwise lethal course. A study on the use of ECMO in the setting of mechanical complications of AMI found a survival rate of 36% in patients placed on ECMO support postoperatively. Although this rate seems low, the chance of survival is near zero if left untreated.[116] These findings are in line with the previously reported 40% survival in the ELSO database, despite the expected greater complexity and risk in post-AMI free wall rupture patients. Several nonrandomized studies support the use of a microaxial flow pump in patients with postcardiotomy shock, with survival ranging around the 60th percentile.[117,118] The paucity of literature on the specific use of microaxial flow pumps following surgical repair of free wall rupture should not limit their placement in such cases. The theoretical risk of rupturing the fresh repair is low, and proper placement and monitoring should mitigate this adverse complication. When using LV tMCS support devices, invasive hemodynamic monitoring is imperative to determine whether escalation to VA-ECMO or a right ventricular tMCS is required. Regardless of the tMCS device chosen, the main determinant of outcome is the early initiation of full cardiopulmonary support when postcardiotomy shock develops after repair.

Statements	Section Free wall rupture	CoR	LoE	% consensus
6.1	Patients with acute free wall rupture with shock physiology should undergo emergent surgical repair.	I	C-EO	100%
6.2	Patients with chronic contained free wall rupture may be initially managed nonoperatively but should be monitored with invasive hemodynamic monitoring and frequent echocardiograms.	IIb	C-EO	100%
6.3	Patients with subacute/chronic free wall rupture with CS may be supported with tMCS prior to surgical intervention.	IIb	C-EO	100%
6.4	Percutaneous pericardial drainage is not recommended in patients with free wall rupture and pericardial tamponade.	III	C-EO	100%
6.5	tMCS, such as a microaxial LVAD or ECMO, may be beneficial for patients with free wall rupture who develop postoperative CS.	IIb	B-NR	85%

Section 7: Management of Ventricular Tachycardia and Refractory Arrhythmia after AMI

Statement 1: Patients with refractory ventricular arrhythmia and CS or cardiac arrest should receive tMCS. (CoR:I, LoE: B-NR)

Refractory ventricular arrythmias are frequently associated with CS. These dysrhythmias may be caused by ischemia, myocardial distension, or diseased conduction pathways. Patients who experience arrythmias are at risk for low cardiac output states and resultant end-organ dysfunction.[119] Although tMCS is unlikely to result in resolution of the rhythm disturbance, it can preserve end-organ function while definitive treatment is arranged.[32,120]

When planning how to support patients in ventricular tachycardia, it is important to consider not only the need for immediate support, but also the future treatment plans. LV function also may impact the choice of support strategy. ECMO can be performed quickly at the bedside and with little need for additional imaging, and will provide rapid biventricular support and halt any ongoing tissue injury. This is the ideal initial support strategy for patients with ventricular arrythmia resulting in a pulseless state necessitating chest compressions.[120] The increased arterial flow increases LV afterload, however, which can result in stasis or distension if LV function is diminished.[121] If time permits, LV unloading with a microaxial flow pump may be considered either as first-line tMCS support or as an adjunct to ECMO support in patients with ventricular dysrhythmia.[122-124]

Statement 2: For patients with recurrent ventricular arrhythmia at risk for sudden hemodynamic decompensation or cardiac arrest who are undergoing ablation, the use of prophylactic tMCS may be reasonable. (CoR: IIb, LoE: C-LD)

Some patients with ventricular arrhythmia are at risk of developing hemodynamic decompensation or cardiac arrest.[119] This risk may be increased during attempted ventricular ablation, especially in patients with electrical storm.[119] For these patients, it is reasonable to consider tMCS as a prophylactic measure.[125] Selection of the appropriate support depends on patient, operator, and institutional factors. Patients with minimal hemodynamic derangement may achieve sufficient support with IABP counterpulsation.[126] This strategy is easy to deploy and uses technology familiar to most team members. More hemodynamic support could be provided by a microaxial flow pump delivered across the aortic valve to directly unload the left ventricle and increase blood flow to the aorta. An obvious limitation to the use of microaxial flow pumps is the need to cross the aortic valve. These devices cannot be used in patients with mechanical aortic valve replacement and may be of limited value in those with severe aortic valvopathy. Additionally, to achieve maximal hemodynamic support, higher-flow microaxial flow pumps require surgical implantation, limiting the rapidity of their deployment.[126] Maximal hemodynamic support can be provided using ECMO or full CPB.[126] In most cases, ECMO will provide sufficient support for the ventricular ablation procedure, and in practice, full CPB is rarely required.[125] Although there are no prospective randomized controlled trials for tMCS in ventricular ablation, observational studies have implied that ventricular arrythmia control and survival are improved with the use of tMCS.[125]

Statement 3: For patients with refractory ventricular arrhythmia either after PCI or in the perioperative period after cardiac surgery, tMCS may be considered. (CoR: IIb, LoE: C-LD)

Ventricular arrhythmia is a common complication of ischemic heart disease. Malignant dysrhythmias can occur during the ischemic insult, after reperfusion, or after scar formation.[127] After an infarct, reentrant circuits exist within surviving myocardial muscle strands throughout the injured zones. These channels of the conducting myocardium have impaired conduction velocity and provide an appropriate milieu for ventricular tachycardia.[127] Reperfusion arrythmias frequently occur after PCI or cardiac surgery.[128]

Rhythm instability may be poorly tolerated hemodynamically postoperatively. Frequent ventricular tachycardia or fibrillation, especially in patients with depressed ventricular function, may inhibit catheter ablation.[129] tMCS may be considered to stabilize patients for catheter ablation. Similar to patients who are not periprocedural, ECMO and microaxial flow pump are the main support options for post-PCI or cardiotomy shock patients.[130,131] There are no large case series describing outcomes for postprocedure patients who require tMCS support during catheter ablation. Single case experiences have reported success with this strategy.[132] Inferring from postcardiotomy ECMO experience, patients requiring ECMO for less than 7 days and those supported only with a microaxial flow pump are most likely to survive to hospital discharge.[133,134] Among nonsurvivors, the most common reason for death was persistent heart failure.[135]

Statement 4: In patients with persistent ventricular arrhythmia after initiation of VA-ECMO, LV venting should be considered using a microaxial flow pump, atrial septostomy, or another method. (CoR: IIa, LoE: B-NR)

VA-ECMO can rapidly halt tissue injury and provide hemodynamic stability for patients in refractory CS of various etiologies.[136] At the same time, increased afterload from VA ECMO support can result in impaired LV emptying and poor myocardial energetics.[137] This increased afterload can be exacerbated by ventricular arrhythmias, which may result in more diminished LV function. Arrhythmias during VA-ECMO may result in LV distension, stasis, and thrombosis.[124] Unloading of the left ventricle may be achieved with IABP counterpulsation, a microaxial flow pump, or LV venting. IABP achieves LV unloading on VA-ECMO by decreasing afterload to the left ventricle during systole.[138] This effect, although modest, may be sufficient to prevent LV distension in some cases. A microaxial flow pump will provide more aggressive LV unloading during VA-ECMO support than can be achieved with an IABP.[139]

Despite this "better" unloading, a meta-analysis of 7 studies with 698 patients did not show a survival benefit from LV unloading with a microaxial

flow pump over an IABP.[139] Similarly, a propensity-matched retrospective multicenter study of 438 patients comparing ECMO alone to ECMO plus microaxial flow pump unloading did not demonstrate a survival advantage over unloading with a microaxial flow pump.[140] Despite these findings, there is evidence that LV unloading with a microaxial flow pump may improve myocardial energetics and possibly increase the likelihood of LV recovery.[141]

Venting of the left ventricle may be achieved by surgical or percutaneous techniques. Surgical techniques include cannulation of the left atrium or the left ventricular apex.[142,143] These strategies provide for excellent unloading of the ventricle but require surgical thoracotomy for cannulation. Percutaneous LV venting techniques include atrial septostomy, atrial septostomy with left atrial cannulation, pulmonary artery venting, and retrograde transaortic valve cannulation.[124,144] None of these strategies has been compared prospectively, and the choice of LV venting technique should be based on operator and institutional experience.

Section 8: The Role of Durable Therapies After AMI

Statement 1: In patients with acute post-AMI heart complications, end-organ stabilization is essential before consideration of long-term advanced therapies, including durable MCS or heart transplantation. (CoR: I, LoE: B-NR)

In patients experiencing acute complications following AMI, stabilizing end-organ function is crucial before considering long-term advanced therapies such as durable MCS and heart transplantation. This approach ensures that patients are in optimal condition to benefit from these interventions and reduces the risk of adverse outcomes. Stabilization of end-organ function mitigates further end-organ damage and failure that may ensue as a result of obligate CPB during durable LVAD or transplantation. Previously, emergent repair was recommended to prevent sudden decompensation, but the significant improvements in tMCS technology have allowed safe bridging to end-organ recovery prior to long-term advanced therapies.[145,146]

Similarly, the 2023 International Society for Heart and Lung Transplantation guidelines for durable MCS emphasize the need to stabilize end-organ function prior to initiating long-term MCS. The guidelines recommend that patients be assessed for reversible causes of organ dysfunction and that stabilization be achieved to improve outcomes with durable MCS.[147]

The American Heart Association's scientific statement on mechanical complications of acute myocardial infarction emphasizes the importance of stabilizing end-organ function. This statement notes that patients with significant end-organ dysfunction may require critical care support to optimize their condition before evaluating them for durable MCS or heart transplantation.[5] Furthermore, in a review of MCS in AMI and CS, the authors discussed the role of tMCS devices in stabilizing patients, suggesting that tMCS can be used to stabilize end-organ function, providing a bridge to more definitive therapies like durable MCS or heart transplantation.[147]

Statement 2: If conventional cardiac surgery is not possible or not successful in patients with acute post-AMI mechanical complications, long-term advanced therapies, including durable MCS or heart transplant, should be considered. (CoR: IIa, LoE: B-NR)

In patients with acute post-AMI mechanical complications in whom conventional cardiac surgery is infeasible or has failed, the use of long-term advanced therapies, such as durable MCS or heart transplantation, should be considered.[148] Durable MCS devices such as LVADs provide effective hemodynamic stabilization and may serve as a bridge to heart transplantation or as destination therapy for patients who are not transplant candidates.[149] Early identification of candidates for these interventions and timely initiation of therapy is essential to optimize outcomes.

Heart transplantation remains the definitive treatment for end-stage heart failure secondary to AMI complications in appropriately selected patients.[148] However, owing to donor organ scarcity and stringent eligibility requirements, not all patients are suitable for transplantation. In these cases, durable MCS offers a viable alternative for improving survival and quality of life.[150,151] Clinical evidence supports the use of LVADs for hemodynamic stabilization, with demonstrated improvements in functional status and successful bridging to transplantation in eligible patients. Given these considerations, durable MCS or heart transplantation should be strongly evaluated as part of the therapeutic approach when conventional surgical options are not viable.

Statement 3: In patients undergoing LVAD implant for acute post-AMI mechanical complications, concomitant surgical procedures (eg, valve surgery, VSD closure, revascularization) should be considered, as indicated. (CoR: IIa, LoE: C-LD)

Patients who develop mechanical complications after AMI, including VSD, papillary muscle, pseudoaneurysm or free wall rupture, represent a complex population with high mortality even in contemporary datasets.[86] When possible, surgical repair of such lesions is the standard of care.[5] When repairs are not possible or when these mechanical complications are accompanied by significant LV dysfunction, patients can be considered for advanced heart failure (AHF) therapies, such as a durable LVAD or heart transplantation. Decision making in these settings should be carried out by multidisciplinary teams with expertise in AHF therapies. The number of patients who have received AHF therapies in the setting of post-AMI mechanical complications is unknown, as larger datasets such as UNOS, EUROMACS, or INTERMACS do not capture this information. Similarly, the evidence to support recommendations in this setting is also limited.

In the case of post-AMI VSD, there are several case reports demonstrating success with simultaneous VSD closure and durable LVAD placement.[152,153] The outcomes of 12 patients with post-AMI VSD who received heart transplantation were summarized in a systematic review published in 2021; however, the in-hospital mortality was 29%, identifying this as a high-risk strategy.[148] In the case of post-AMI papillary muscle rupture, there is more evidence for temporary LVAD use as a bridge to surgical

ADULT

Statements	Section Ventricular tachycardia/refractory arrhythmia	CoR	LoE	% consensus
7.1	Patients with refractory ventricular arrhythmia and CS or cardiac arrest should receive tMCS.	I	B-NR	92%
7.2	For patients with recurrent ventricular arrhythmia at risk for sudden hemodynamic decompensation or cardiac arrest who are undergoing ablation, prophylactic tMCS may be reasonable.	IIb	C-LD	100%
7.3	For patients with refractory ventricular arrhythmia either after PCI or in the perioperative period after cardiac surgery, tMCS may be considered.	IIb	C-LD	100%
7.4	In patients with persistent ventricular arrhythmia after initiation of VA ECMO, LV venting using a microaxial flow pump, atrial septostomy, or other method should be considered.	IIa	B-NR	92%

valve replacement than a direct-to-AHF therapy strategy.[154,155] This use makes sense, as durable LVAD and heart transplantation should be avoided when LV recovery is still possible. If patients are proceeding with durable LVAD after a post MI mechanical complication, it is recommended to repair such lesions (ie, papillary muscle rupture, pseudoaneurysm or VSD) at the time of LVAD implantation to ensure optimal LVAD function, although the data for this recommendation are also limited.[156,157]

Statement 4: A total artificial heart (TAH) may be considered as an option in select settings of acute post-AMI mechanical complications if severe biventricular dysfunction or LV anatomic issues preclude LVAD implantation and the patient is not an imminent transplant candidate. (CoR: IIb, LoE: C-LD)

A subgroup of AMI patients has additional complications that preclude tMCS and definitive repair. These complications include presence of aortic insufficiency, endocarditis, left ventricular thrombus, and intractable ventricular arrhythmias. The SynCardia Total Artificial Heart (TAH; SynCardia Systems) is currently the only Food and Drug Administration–approved device that can be used in this patient population to provide life-sustaining support.[158] There are case reports describing the use of 2 HeartMate 3 devices to provide biventricular support, but these devices are not approved for this indication. The TAH is currently approved as a bridge to transplant or as a humanitarian use device for destination (HUD) therapy.

The TAH is sewn to the atria, aorta, and pulmonary artery; thus, all mechanical and structural issues can be removed during implantation. Between 2006 and 2017, of the 450 patients with TAH implants reported to the INTERMACS database, 80% were classified as Profile INTERMACS 1 or 2. In one study, 266 patients eventually underwent TAH implantation, and 162 died. Risk factors for death included older age, need for preimplantation dialysis, liver dysfunction with low albumin, or implantation at a low volume (<10 TAHs) center.[159] Main causes of death included multisystem organ failure, neurologic injury, withdrawal of support, and infection. In patients with mechanical complications of AMI who cannot be optimized and repaired, the TAH can be used to provide support and serve as a potential bridge to transplantation.[159-161]

DISCUSSION

AMI remains an important health problem. The overall mortality due to AMI and the incidence of associated mechanical complications have decreased over the past several decades.[5,82] These observations may be attributable in part to the broad implementation of rapid restoration of myocardial perfusion. While the incidence of complications associated with AMI has decreased, data are conflicting on whether mortality due to these complications has improved.[5]

Our systemic literature search aimed to identify recommendations from international panels of experts on contemporary management of complications of AMI, with a particular focus on the use of tMCS. Based on our analysis of the existing literature, several important concepts have emerged. First, although prior guidelines advocated for urgent surgical intervention in the presence of CS, our review of current data suggests that tMCS can be useful in the initial management of patients with CS, refractory arrythmia, or mechanical complications due to AMI.[162] tMCS strategies may be tailored to suit each individual patient. In cases where CS is a predominant feature resulting from AMI, axial temporary LVAD may be advantageous, as this strategy may be best suited for LV unloading. These devices may be used as a sole support strategy or in combination with VA-ECMO. VA-ECMO or a biventricular tMCS device may be required if biventricular failure or refractory ventricular arrythmias occur. In any case, temporary support modalities may be implemented to provide hemodynamic stabilization and allow subsequent PCI and/or definitive surgical intervention.

Second, a CS team-based approach may be useful in determining the optimal management strategy for individual patients with complications of AMI. Heart teams have been instituted to help determine the best strategy for managing individual patients in scenarios where different potential interventions exist. For example, heart team approaches have been used for decision making for patients with coronary and valvular heart disease.[163-166] Medical, interventional, and surgical options also are available for patients with pulmonary embolus, and team-based approaches to these patients also have emerged and demonstrated utility.[167,168] Much like for acute pulmonary

Statements	Section Durable therapies: VAD, TAH	CoR	LoE	% consensus
8.1	In patients with acute post-AMI heart complications, end-organ stabilization is essential before consideration of long-term advanced therapies, including durable MCS or heart transplant.	I	B-NR	100%
8.2	If conventional cardiac surgery is not possible or not successful in patients with acute post-AMI mechanical complications, long-term advanced therapies, including durable MCS or heart transplant, should be considered.	IIa	B-NR	92%
8.3	In patients undergoing LVAD implantation for acute post-AMI mechanical complications, concomitant surgical procedures (eg, valve surgery, VSD closure, revascularization) should be considered, as indicated.	IIa	C-LD	100%
8.4	TAH may be considered as an option in selected settings of acute post-AMI mechanical complications if severe biventricular dysfunction or LV anatomical issues preclude LVAD insertion and the patient is not an imminent transplant candidate.	IIb	C-LD	77%

embolism, decisions surrounding the management of complications of AMI also may be very time-sensitive. Clearly, while team-based approaches may facilitate decision making, complications of AMI must be addressed expeditiously.

Furthermore, in the setting of mechanical complications, patients should be stabilized and optimized prior to operative intervention. Medical therapy and possibly tMCS may be necessary. In situations when native heart recovery cannot be achieved or when conventional cardiac surgical interventions are not possible, the use of durable therapies can be considered. These therapies may include LVAD, heart transplant, or TAH. However, prior to consideration of these therapies, alternative options, including revascularization or surgical intervention, should be exhausted.

A number of questions merit further exploration. Specifically, the duration of when native heart recovery can no longer be expected after AMI complicated by CS has not been well defined. Also, the optimal interval from AMI to definitive therapy for mechanical complications is unclear and may vary depending on the specific complication. Similarly, the optimal interval from the time of initiation of support on tMCS to receipt of heart transplant, VAD, or TAH remains undefined. In these settings, hemodynamic stabilization and optimization of end-organ function are primary goals.

Another important consideration is the need for escalation or addition of mechanical support modalities. For example, if a patient is supported with an isolated temporary LVAD and develops signs of right heart failure (as evidenced by high right-sided filling pressures that are refractory to medical management, particularly in the setting of poor right ventricular function on echocardiography and worsening hepatic and renal function), then right-sided mechanical support should be considered. The use of either a temporary right ventricular assist device or VA-ECMO may be appropriate depending on the circumstances and patient characteristics. Moreover, if a patient is initially supported with an isolated left or right temporary ventricular assist device but develops refractory ventricular arrhythmia, then escalation also may be necessary. Specific thresholds for the addition or escalation of support modalities remains an area of active investigation and merits further study.

The care of patients with complications of AMI is clearly resource-intensive, particularly when multiple mechanical support modalities are required. Delivery of cost-effective care is an important consideration. A better understanding of factors that define futility in this setting is required and also merits further research.

Complications of AMI still carry an unacceptably high mortality. Ongoing investigations into the optimal use of existing technology and paradigms for treating patients with complications of AMI, as well as implementation of novel strategies, will be necessary to mitigate this high rate of mortality. As percutaneous and less invasive strategies to treat structural heart disease and novel MCS devices are developed, we expect management of complications of AMI to evolve as well.

Webcast

You can watch a Webcast of this AATS meeting presentation by going to: Xxx.

Conflict of Interest Statement

The authors reported no conflicts of interest.

The *Journal* policy requires editors and reviewers to disclose conflicts of interest and to decline handling or reviewing manuscripts for which they may have a conflict of interest. The editors and reviewers of this article have no conflicts of interest.

References

1. Henry TD, Tomey MI, Tamis-Holland JE, et al. Invasive management of acute myocardial infarction complicated by cardiogenic shock: a scientific statement from the American Heart Association. *Circulation*. 2021;143(15):e815-e829. https://doi.org/10.1161/cir.0000000000000959
2. Thiele H, Zeymer U, Neumann FJ, et al. Intraaortic balloon support for myocardial infarction with cardiogenic shock. *N Engl J Med*. 2012;367(14):1287-1296. https://doi.org/10.1056/NEJMoa1208410
3. Thiele H, Akin I, Sandri M, et al. PCI strategies in patients with acute myocardial infarction and cardiogenic shock. *N Engl J Med*. 2017;377(25):2419-2432. https://doi.org/10.1056/NEJMoa1710261
4. van Diepen S, Katz JN, Albert NM, et al. Contemporary management of cardiogenic shock: a scientific statement from the American Heart Association. *Circulation*. 2017;136(16):e232-e268. https://doi.org/10.1161/cir.0000000000000525
5. Damluji AA, van Diepen S, Katz JN, et al. Mechanical complications of acute myocardial infarction: a scientific statement from the American Heart Association. *Circulation*. 2021;144(2):e16-e35. https://doi.org/10.1161/cir.0000000000000985
6. Gong FF, Vaitenas I, Malaisrie SC, Maganti K. Mechanical complications of acute myocardial infarction: a review. *JAMA Cardiol*. 2021;6(3):341-349. https://doi.org/10.1001/jamacardio.2020.3690
7. Thiele H, Zeymer U, Akin I, et al. Extracorporeal life support in infarct-related cardiogenic shock. *N Engl J Med*. 2023;389(14):1286-1297. https://doi.org/10.1056/NEJMoa2307227
8. Møller JE, Engstrøm T, Jensen LO, et al. Microaxial flow pump or standard care in infarct-related cardiogenic shock. *N Engl J Med*. 2024;390(15):1382-1393. https://doi.org/10.1056/NEJMoa2312572
9. Milojevic M, Freemantle N, Hayanga JWA, et al. Harmonizing guidelines and other clinical practice documents: a joint comprehensive methodology manual by the American association for Thoracic Surgery (AATS), European Association for Cardio-Thoracic Surgery (EACTS), European Society of Thoracic Surgeons (ESTS), and Society of Thoracic Surgeons (STS). *J Thorac Cardiovasc Surg*. 2025;169(1):170-185. https://doi.org/10.1016/j.jtcvs.2024.07.048
10. Bakaeen FG, Svensson LG, Mitchell JD, Keshavjee S, Patterson GA, Weisel RD. The American Association for Thoracic Surgery/Society of Thoracic Surgeons position statement on developing clinical practice documents. *J Thorac Cardiovasc Surg*. 2017;153(4):999-1005. https://doi.org/10.1016/j.jtcvs.2017.01.003
11. Bakaeen FG, Svensson LG, Mitchell JD, Keshavjee S, Patterson GA, Weisel RD. The American Association for Thoracic Surgery/Society of Thoracic Surgeons position statement on developing clinical practice documents. *Ann Thorac Surg*. 2017;103(4):1350-1356. https://doi.org/10.1016/j.athoracsur.2017.01.020
12. Guyatt GH, Oxman AD, Vist GE, et al. GRADE: an emerging consensus on rating quality of evidence and strength of recommendations. *BMJ*. 2008;336(7650):924-926. https://doi.org/10.1136/bmj.39489.470347.AD
13. Jones J, Hunter D. Consensus methods for medical and health services research. *BMJ*. 1995;311(7001):376-380. https://doi.org/10.1136/bmj.311.7001.376
14. Fu D, Stawiarski K, Núñez Gil IJ, Ramakrishna H. Cardiogenic shock update: new trials, evolving management paradigms, and artificial intelligence.

ADULT

J Cardiothorac Vasc Anesth. 2024;38(9):2100-2104. https://doi.org/10.1053/j.jvca.2024.06.008
15. Varma B, Katz JN, Alviar CL. Building a cardiogenic shock response team: key considerations necessary to improve outcomes. *Curr Opin Crit Care*. 2024;30(4):354-361. https://doi.org/10.1097/mcc.0000000000001177
16. Senman B, Jentzer JC, Barnett CF, et al. Need for a cardiogenic shock team collaborative-promoting a team-based model of care to improve outcomes and identify best practices. *J Am Heart Assoc*. 2024;13(6):e031979. https://doi.org/10.1161/jaha.123.031979
17. Basir MB, Kapur NK, Patel K, et al. Improved outcomes associated with the use of shock protocols: updates from the National Cardiogenic Shock Initiative. *Catheter Cardiovasc Interv*. 2019;93(7):1173-1183. https://doi.org/10.1002/ccd.28307
18. Tehrani BN, Truesdell AG, Sherwood MW, et al. Standardized team-based care for cardiogenic shock. *J Am Coll Cardiol*. 2019;73(13):1659-1669. https://doi.org/10.1016/j.jacc.2018.12.084
19. Taleb I, Koliopoulou AG, Tandar A, et al. Shock team approach in refractory cardiogenic shock requiring short-term mechanical circulatory support: a proof of concept. *Circulation*. 2019;140(1):98-100. https://doi.org/10.1161/circulationaha.119.040654
20. Taleb I, Giannouchos TV, Kyriakopoulos CP, et al. Cost-effectiveness of a shock team approach in refractory cardiogenic shock. *Circ Heart Fail*. 2024;17(11):e011709. https://doi.org/10.1161/circheartfailure.124.011709
21. Faridi KF, Rymer JA, Rao SV, et al. Ad hoc percutaneous coronary intervention in patients with stable coronary artery disease: a report from the National Cardiovascular Data Registry CathPCI Registry. *Am Heart J*. 2019;216:53-61. https://doi.org/10.1016/j.ahj.2019.07.004
22. Luckraz H, Norell M, Buch M, James R, Cooper G. Structure and functioning of a multidisciplinary 'Heart Team' for patients with coronary artery disease: rationale and recommendations from a joint BCS/BCIS/SCTS working group. *Eur J Cardiothorac Surg*. 2015;48(4):524-529. https://doi.org/10.1093/ejcts/ezv083
23. Lawton JS, Tamis-Holland JE, Bangalore S, et al. 2021 ACC/AHA/SCAI guideline for coronary artery revascularization: a report of the American College of Cardiology/American Heart Association Joint Committee on Clinical Practice Guidelines. *Circulation*. 2022;145(3):e18-e114. https://doi.org/10.1161/cir.0000000000001038
24. Maron DJ, Hochman JS, Reynolds HR, et al. Initial invasive or conservative strategy for stable coronary disease. *N Engl J Med*. 2020;382(15):1395-1407. https://doi.org/10.1056/NEJMoa1915922
25. O'Neill WW, Kleiman NS, Moses J, et al. A prospective, randomized clinical trial of hemodynamic support with Impella 2.5 versus intra-aortic balloon pump in patients undergoing high-risk percutaneous coronary intervention: the PROTECT II study. *Circulation*. 2012;126(14):1717-1727. https://doi.org/10.1161/circulationaha.112.098194
26. Lansky AJ, Tirziu D, Moses JW, et al. Impella versus intra-aortic balloon pump for high-risk PCI: a propensity-adjusted large-scale claims dataset analysis. *Am J Cardiol*. 2022;185:29-36. https://doi.org/10.1016/j.amjcard.2022.08.032
27. Montisci A, Panoulas V, Chieffo A, et al. Recognizing patients as candidates for temporary mechanical circulatory support along the spectrum of cardiogenic shock. *Eur Heart J Suppl*. 2023;25(Suppl I):I3-I10. https://doi.org/10.1093/eurheartjsupp/suad127
28. Okamoto N, Egami Y, Sugino A, et al. Impact of prereperfusion left ventricle unloading on ST-segment elevation myocardial infarction according to the onset-to-unloading time. *Am J Cardiol*. 2025;239:43-50. https://doi.org/10.1016/j.amjcard.2024.12.003
29. Singh SK, Vinogradsky A, Kirschner M, et al. Mechanical circulatory support during surgical revascularization for ischemic cardiomyopathy. *Ann Thorac Surg*. 2024;117(5):932-939. https://doi.org/10.1016/j.athoracsur.2024.01.017
30. Pieri M, D'Andria Ursoleo J, Nardelli P, et al. Temporary mechanical circulatory support with Impella in cardiac surgery: a systematic review. *Int J Cardiol*. 2024;396:131418. https://doi.org/10.1016/j.ijcard.2023.131418
31. Merchant RM, Topjian AA, Panchal AR, et al. Part 1: executive summary: 2020 American Heart Association guidelines for cardiopulmonary resuscitation and emergency cardiovascular care. *Circulation*. 2020;142(16_suppl_2):S337-S357. https://doi.org/10.1161/cir.0000000000000918
32. Yannopoulos D, Bartos J, Raveendran G, et al. Advanced reperfusion strategies for patients with out-of-hospital cardiac arrest and refractory ventricular fibrillation (ARREST): a phase 2, single centre, open-label, randomised controlled trial. *Lancet*. 2020;396(10265):1807-1816. https://doi.org/10.1016/s0140-6736(20)32338-2
33. Belohlavek J, Smalcova J, Rob D, et al. Effect of intra-arrest transport, extracorporeal cardiopulmonary resuscitation, and immediate invasive assessment and treatment on functional neurologic outcome in refractory out-of-hospital cardiac arrest: a randomized clinical trial. *JAMA*. 2022;327(8):737-747. https://doi.org/10.1001/jama.2022.1025
34. Suverein MM, Delnoij TSR, Lorusso R, et al. Early extracorporeal CPR for refractory out-of-hospital cardiac arrest. *N Engl J Med*. 2023;388(4):299-309. https://doi.org/10.1056/NEJMoa2204511
35. Søholm H, Wachtell K, Nielsen SL, et al. Tertiary centres have improved survival compared to other hospitals in the Copenhagen area after out-of-hospital cardiac arrest. *Resuscitation*. 2013;84(2):162-167. https://doi.org/10.1016/j.resuscitation.2012.06.029
36. Fujii M, Okino S, Sakata T, Mogi K, Sakurai M, Takahara Y. Safety and efficacy of surgical revascularization with percutaneous ventricular assist device for acute myocardial infarction complicated by cardiogenic shock: Japanese national registry study. *Artif Organs*. 2025;49(3):516-524. https://doi.org/10.1111/aor.14901
37. Engdahl J, Abrahamsson P, Bång A, Lindqvist J, Karlsson T, Herlitz J. Is hospital care of major importance for outcome after out-of-hospital cardiac arrest? Experience acquired from patients with out-of-hospital cardiac arrest resuscitated by the same Emergency Medical Service and admitted to one of two hospitals over a 16-year period in the municipality of Göteborg. *Resuscitation*. 2000;43(3):201-211. https://doi.org/10.1016/s0300-9572(99)00154-9
38. Herlitz J, Engdahl J, Svensson L, Angquist KA, Silfverstolpe J, Holmberg S. Major differences in 1-month survival between hospitals in Sweden among initial survivors of out-of-hospital cardiac arrest. *Resuscitation*. 2006;70(3):404-409. https://doi.org/10.1016/j.resuscitation.2006.01.014
39. Tarzia V, Bagozzi L, Ponzoni M, et al. Prognosticating mortality of primary cardiogenic shock requiring extracorporeal life support: the RESCUE score. *Curr Probl Cardiol*. 2023;48(4):101554. https://doi.org/10.1016/j.cpcardiol.2022.101554
40. Sun D, Wei C, Li Z. Blood urea nitrogen to creatinine ratio is associated with in-hospital mortality among critically ill patients with cardiogenic shock. *BMC Cardiovasc Disord*. 2022;22(1):258. https://doi.org/10.1186/s12872-022-02692-9
41. Vallabhajosyula S, Dunlay SM, Prasad A, et al. Acute noncardiac organ failure in acute myocardial infarction with cardiogenic shock. *J Am Coll Cardiol*. 2019;73(14):1781-1791. https://doi.org/10.1016/j.jacc.2019.01.053
42. Zweck E, Thayer KL, Helgestad OKL, et al. Phenotyping cardiogenic shock. *J Am Heart Assoc*. 2021;10(14):e020085. https://doi.org/10.1161/jaha.120.020085
43. Baran DA, Grines CL, Bailey S, et al. SCAI clinical expert consensus statement on the classification of cardiogenic shock: this document was endorsed by the American College of Cardiology (ACC), the American heart Association (AHA), the Society of Critical Care Medicine (SCCM), and the Society of Thoracic Surgeons (STS) in April 2019. *Catheter Cardiovasc Interv*. 2019;94(1):29-37. https://doi.org/10.1002/ccd.28329
44. Yamazaki Y, Oba K, Matsui Y, Morimoto Y. Vasoactive-inotropic score as a predictor of morbidity and mortality in adults after cardiac surgery with cardiopulmonary bypass. *J Anesth*. 2018;32(2):167-173. https://doi.org/10.1007/s00540-018-2447-2
45. Kwon JH, Yoo SY, Kim S, et al. Vasoactive inotropic score as a predictor of long-term mortality in patients after off-pump coronary artery bypass grafting. *Sci Rep*. 2022;12(1):12863. https://doi.org/10.1038/s41598-022-16900-1
46. Kapur NK, Kanwar M, Sinha SS, et al. Criteria for defining stages of cardiogenic shock severity. *J Am Coll Cardiol*. 2022;80(3):185-198. https://doi.org/10.1016/j.jacc.2022.04.049
47. Naidu SS, Baran DA, Jentzer JC, et al. SCAI SHOCK stage classification expert consensus update: a review and incorporation of validation studies: This statement was endorsed by the American College of Cardiology (ACC), American College of Emergency Physicians (ACEP), American Heart Association (AHA), European Society of Cardiology (ESC) Association for Acute Cardiovascular Care (ACVC), International Society for Heart and Lung Transplantation (ISHLT), Society of Critical Care Medicine (SCCM), and Society of Thoracic Surgeons (STS) in December 2021. *J Am Coll Cardiol*. 2022;79(9):933-946. https://doi.org/10.1016/j.jacc.2022.01.018
48. Valente S, Lazzeri C, Vecchio S, et al. Predictors of in-hospital mortality after percutaneous coronary intervention for cardiogenic shock. *Int J Cardiol*. 2007;114(2):176-182. https://doi.org/10.1016/j.ijcard.2006.01.024
49. Hussain F, Philipp RK, Ducas RA, et al. The ability to achieve complete revascularization is associated with improved in-hospital survival in cardiogenic shock due to myocardial infarction: Manitoba cardiogenic SHOCK Registry

ADULT

Investigators. *Catheter Cardiovasc Interv*. 2011;78(4):540-548. https://doi.org/10.1002/ccd.23006
50. Park IH, Yang JH, Jang WJ, et al. Clinical significance of lactate clearance in patients with cardiogenic shock: results from the RESCUE registry. *J Intensive Care*. 2021;9(1):63. https://doi.org/10.1186/s40560-021-00571-7
51. Basir MB, Lemor A, Gorgis S, et al. Early utilization of mechanical circulatory support in acute myocardial infarction complicated by cardiogenic shock: the National Cardiogenic Shock Initiative. *J Am Heart Assoc*. 2023;12(23):e031401. https://doi.org/10.1161/jaha.123.031401
52. Ouweneel DM, de Brabander J, Karami M, et al. Real-life use of left ventricular circulatory support with Impella in cardiogenic shock after acute myocardial infarction: 12 years AMC experience. *Eur Heart J Acute Cardiovasc Care*. 2019;8(4):338-349. https://doi.org/10.1177/2048872618805486
53. Hernández-Pérez FJ, Álvarez-Avelló JM, Forteza A, et al. Initial outcomes of a multidisciplinary network for the care of patients with cardiogenic shock. *Rev Esp Cardiol (Engl Ed)*. 2021;74(1):33-43. https://doi.org/10.1016/j.rec.2020.03.010
54. Kim E, Sodirzhon-Ugli NY, Kim DW, et al. Prediction of 6-month mortality using pre-extracorporeal membrane oxygenation lactate in patients with acute coronary syndrome undergoing veno-arterial-extracorporeal membrane oxygenation. *J Chest Surg*. 2022;55(2):143-150. https://doi.org/10.5090/jcs.21.127
55. von Lewinski D, Herold L, Stoffel C, et al. PRospective REgistry of PAtients in REfractory cardiogenic shock-The PREPARE CardShock registry. *Catheter Cardiovasc Interv*. 2022;100(3):319-327. https://doi.org/10.1002/ccd.30327
56. Dib N, Belaroussi Y, Mansour A, et al. Association of arterial blood pH at cannulation with 1 year survival among veno-arterial extracorporeal membrane oxygenation recipients: the three seven rule. *ASAIO J*. 2023;69(7):e287-e292. https://doi.org/10.1097/mat.0000000000001964
57. Fux T, Holm M, Corbascio M, Lund LH, van der Linden J. Venoarterial extracorporeal membrane oxygenation for postcardiotomy shock: risk factors for mortality. *J Thorac Cardiovasc Surg*. 2018;156(5):1894-1902.e3. https://doi.org/10.1016/j.jtcvs.2018.05.061
58. Dennis M, Buscher H, Gattas D, et al. Prospective observational study of mechanical cardiopulmonary resuscitation, extracorporeal membrane oxygenation and early reperfusion for refractory cardiac arrest in Sydney: the 2CHEER study. *Crit Care Resusc*. 2020;22(1):26-34. https://doi.org/10.51893/2020.1.oa3
59. Low CJW, Ramanathan K, Ling RR, et al. Extracorporeal cardiopulmonary resuscitation versus conventional cardiopulmonary resuscitation in adults with cardiac arrest: a comparative meta-analysis and trial sequential analysis. *Lancet Respir Med*. 2023;11(10):883-893. https://doi.org/10.1016/s2213-2600(23)00137-6
60. Rob D, Smalcova J, Smid O, et al. Extracorporeal versus conventional cardiopulmonary resuscitation for refractory out-of-hospital cardiac arrest: a secondary analysis of the Prague OHCA trial. *Crit Care*. 2022;26(1):330. https://doi.org/10.1186/s13054-022-04199-3
61. Scquizzato T, Bonaccorso A, Swol J, et al. Refractory out-of-hospital cardiac arrest and extracorporeal cardiopulmonary resuscitation: a meta-analysis of randomized trials. *Artif Organs*. 2023;47(5):806-816. https://doi.org/10.1111/aor.14516
62. Archilletti F, Giuliani L, Dangas GD, et al. Timing of mechanical circulatory support during primary angioplasty in acute myocardial infarction and cardiogenic shock: systematic review and meta-analysis. *Catheter Cardiovasc Interv*. 2022;99(4):998-1005. https://doi.org/10.1002/ccd.30137
63. Huang CC, Hsu JC, Wu YW, et al. Implementation of extracorporeal membrane oxygenation before primary percutaneous coronary intervention may improve the survival of patients with ST-segment elevation myocardial infarction and refractory cardiogenic shock. *Int J Cardiol*. 2018;269:45-50. https://doi.org/10.1016/j.ijcard.2018.07.023
64. Kim MC, Ahn Y, Cho KH, et al. Benefit of extracorporeal membrane oxygenation before revascularization in patients with acute myocardial infarction complicated by profound cardiogenic shock after resuscitated cardiac arrest. *Korean Circ J*. 2021;51(6):533-544. https://doi.org/10.4070/kcj.2020.0499
65. Tsao NW, Shih CM, Yeh JS, et al. Extracorporeal membrane oxygenation-assisted primary percutaneous coronary intervention may improve survival of patients with acute myocardial infarction complicated by profound cardiogenic shock. *J Crit Care*. 2012;27(5):530.e1-530.e11. https://doi.org/10.1016/j.jcrc.2012.02.012
66. Choi KH, Yang JH, Hong D, et al. Optimal timing of venoarterial-extracorporeal membrane oxygenation in acute myocardial infarction patients suffering from refractory cardiogenic shock. *Circ J*. 2020;84(9):1502-1510. https://doi.org/10.1253/circj.CJ-20-0259
67. Dobrilovic N, Lateef O, Michalak L, Delibasic M, Raman J. Extracorporeal membrane oxygenation bridges inoperable patients to definitive cardiac operation. *ASAIO J*. 2019;65(1):43-48. https://doi.org/10.1097/mat.0000000000000741
68. Hamiko M, Slottosch I, Scherner M, et al. Timely extracorporeal membrane oxygenation assist reduces mortality after bypass surgery in patients with acute myocardial infarction. *J Card Surg*. 2019;34(11):1243-1255. https://doi.org/10.1111/jocs.14258
69. Thiele H, Zeymer U, Thelemann N, et al. Intraaortic balloon pump in cardiogenic shock complicating acute myocardial infarction: long-term 6-year outcome of the randomized IABP-SHOCK II trial. *Circulation*. 2019;139(3):395-403. https://doi.org/10.1161/circulationaha.118.038201
70. Thiele H, Zeymer U, Neumann FJ, et al. Intra-aortic balloon counterpulsation in acute myocardial infarction complicated by cardiogenic shock (IABP-SHOCK II): final 12 month results of a randomised, open-label trial. *Lancet*. 2013;382(9905):1638-1645. https://doi.org/10.1016/s0140-6736(13)61783-3
71. Na SJ, Chung CR, Cho YH, et al. Vasoactive inotropic score as a predictor of mortality in adult patients with cardiogenic shock: medical therapy versus ECMO. *Rev Esp Cardiol (Engl Ed)*. 2019;72(1):40-47. https://doi.org/10.1016/j.rec.2018.01.003
72. Choi KH, Yang JH, Park TK, et al. Differential prognostic implications of vasoactive inotropic score for patients with acute myocardial infarction complicated by cardiogenic shock according to use of mechanical circulatory support. *Crit Care Med*. 2021;49(5):770-780. https://doi.org/10.1097/ccm.0000000000004815
73. Yeo I, Axman R, Lu DY, et al. Impella versus intra-aortic balloon pump in patients with cardiogenic shock treated with venoarterial extracorporeal membrane oxygenation: an observational study. *J Am Heart Assoc*. 2024;13(3):e032607. https://doi.org/10.1161/jaha.123.032607
74. Nishi T, Ishii M, Tsujita K, et al. Outcomes of venoarterial extracorporeal membrane oxygenation plus intra-aortic balloon pumping for treatment of acute myocardial infarction complicated by cardiogenic shock. *J Am Heart Assoc*. 2022;11(7):e023713. https://doi.org/10.1161/jaha.121.023713
75. Koeda Y, Itoh T, Ishikawa Y, et al. A multicenter study on the clinical characteristics and risk factors of in-hospital mortality in patients with mechanical complications following acute myocardial infarction. *Heart Vessels*. 2020;35(8):1060-1069. https://doi.org/10.1007/s00380-020-01586-0
76. Pahuja M, Ranka S, Chauhan K, et al. Rupture of papillary muscle and chordae tendinae complicating STEMI: a call for action. *ASAIO J*. 2021;67(8):907-916. https://doi.org/10.1097/mat.0000000000001299
77. Kettner J, Sramko M, Holek M, Pirk J, Kautzner J. Utility of intra-aortic balloon pump support for ventricular septal rupture and acute mitral regurgitation complicating acute myocardial infarction. *Am J Cardiol*. 2013;112(11):1709-1713. https://doi.org/10.1016/j.amjcard.2013.07.035
78. Ng R, Yeghiazarians Y. Post myocardial infarction cardiogenic shock: a review of current therapies. *J Intensive Care Med*. 2013;28(3):151-165. https://doi.org/10.1177/0885066611411407
79. Nakata J, Saku K, Nishikawa T, et al. Substantial reduction of acute ischemic mitral regurgitation using Impella in AMI complicated with cardiogenic shock. *Int Heart J*. 2023;64(2):294-298. https://doi.org/10.1536/ihj.22-572
80. Fujimoto K, Kawahito K, Yamaguchi A, et al. Percutaneous extracorporeal life support for treatment of fatal mechanical complications associated with acute myocardial infarction. *Artif Organs*. 2001;25(12):1000-1003. https://doi.org/10.1046/j.1525-1594.2001.06792.x
81. Buerke M, Prondzinsky R, Lemm H, et al. Intra-aortic balloon counterpulsation in the treatment of infarction-related cardiogenic shock–review of the current evidence. *Artif Organs*. 2012;36(6):505-511. https://doi.org/10.1111/j.1525-1594.2011.01408.x
82. Tripathi B, Aggarwal V, Abbott JD, et al. Mechanical complications in ST-elevation myocardial infarction (STEMI) based on different reperfusion strategies. *Am J Cardiol*. 2021;156:79-84. https://doi.org/10.1016/j.amjcard.2021.06.012
83. Bouma W, Wijdh-den Hamer IJ, Koene BM, et al. Predictors of in-hospital mortality after mitral valve surgery for post-myocardial infarction papillary muscle rupture. *J Cardiothorac Surg*. 2014;9:171. https://doi.org/10.1186/s13019-014-0171-z
84. Kutty RS, Jones N, Moorjani N. Mechanical complications of acute myocardial infarction. *Cardiol Clin*. 2013;31(4):519-531, vii-viii. https://doi.org/10.1016/j.ccl.2013.07.004
85. Bhardwaj B, Sidhu G, Balla S, et al. Outcomes and hospital utilization in patients with papillary muscle rupture associated with acute myocardial infarction. *Am J Cardiol*. 2020;125(7):1020-1025. https://doi.org/10.1016/j.amjcard.2019.12.051

ADULT

86. Elbadawi A, Elgendy IY, Mahmoud K, et al. Temporal trends and outcomes of mechanical complications in patients with acute myocardial infarction. *JACC Cardiovasc Interv*. 2019;12(18):1825-1836. https://doi.org/10.1016/j.jcin.2019.04.039
87. Chen Q, Darlymple-Hay MJ, Alexiou C, et al. Mitral valve surgery for acute papillary muscle rupture following myocardial infarction. *J Heart Valve Dis*. 2002;11(1):27-31.
88. So CY, Kang G, Lee JC, et al. Transcatheter edge-to-edge repair for acute mitral regurgitation with cardiogenic shock secondary to mechanical complication. *Cardiovasc Revasc Med*. 2022;45:44-50. https://doi.org/10.1016/j.carrev.2022.07.003
89. Flint K, Brieke A, Wiktor D, Carroll J. Percutaneous edge-to-edge mitral valve repair may rescue select patients in cardiogenic shock: findings from a single center case series. *Catheter Cardiovasc Interv*. 2019;94(2):e82-e87. https://doi.org/10.1002/ccd.28089
90. Hernández-Enríquez M, Freixa X, Sanchis L, et al. MitraClip® repair in cardiogenic shock due to acute mitral regurgitation: from near-death to walking. *J Heart Valve Dis*. 2018;27(1):114-116.
91. Coughlin RF, Peaper D, Rothenberg C, et al. Electronic health record-assisted reflex urine culture testing improves emergency department diagnostic efficiency. *Am J Med Qual*. 2020;35(3):252-257. https://doi.org/10.1177/1062860619861947
92. Gold HK, Leinbach RC, Sanders CA, Buckley MJ, Mundth ED, Austen WG. Intraaortic balloon pumping for ventricular septal defect or mitral regurgitation complicating acute myocardial infarction. *Circulation*. 1973;47(6):1191-1196. https://doi.org/10.1161/01.cir.47.6.1191
93. McLaughlin A, McGiffin D, Winearls J, et al. Veno-arterial ECMO in the setting of post-infarct ventricular septal defect: a bridge to surgical repair. *Heart Lung Circ*. 2016;25(11):1063-1066. https://doi.org/10.1016/j.hlc.2016.02.024
94. Pahuja M, Schrage B, Westermann D, Basir MB, Garan AR, Burkhoff D. Hemodynamic effects of mechanical circulatory support devices in ventricular septal defect. *Circ Heart Fail*. 2019;12(7):e005981. https://doi.org/10.1161/circheartfailure.119.005981
95. Delmas C, Barbosa H, David CH, et al. Impella for the management of ventricular septal defect complicating acute myocardial infarction: a European multicenter registry. *ASAIO J*. 2023;69(12):e491-e499. https://doi.org/10.1097/mat.0000000000002060
96. Dimarakis I, Adcox M, Pal JD, Khorsandi M. Impella 5.5 support before, during, and after surgical ventricular septal defect repair: a bridge continuum. *Perfusion*. 2024;39(6):1270-1273. https://doi.org/10.1177/02676591231182248
97. Via G, Buson S, Tavazzi G, et al. Early cardiac unloading with ImpellaCP™ in acute myocardial infarction with ventricular septal defect. *ESC Heart Fail*. 2020;7(2):708-713. https://doi.org/10.1002/ehf2.12622
98. Sato S, Hiraoka A, Toki M, Chikazawa G, Yoshitaka H. Right-to-left shunt depending on the support level of Impella for post-infarction ventricular septal defect. *Eur Heart J Cardiovasc Imaging*. 2022;23(8):e296. https://doi.org/10.1093/ehjci/jeac084
99. Ruiz Duque E, Hohenwarter MR, Isom NR, Singhal AK. Impella support for surgical ventricular septal defect repair. *ASAIO J*. 2023;69(6):e278-e283. https://doi.org/10.1097/mat.0000000000001873
100. Jalli S, Spinelli KJ, Kirker EB, Venkataraman A, Abraham J. Impella as a bridge-to-closure in post-infarction ventricular septal defect: a case series. *Eur Heart J Case Rep*. 2023;7(10):ytad500. https://doi.org/10.1093/ehjcr/ytad500
101. Madjarov JM, Katz MG, Madzharov S, Fazal S, Robicsek F. Advantages of intraoperative implantation of Impella 5.5 SmartAssist in the management of acute post-infarction ventricular septal defect with cardiogenic shock. *J Cardiothorac Surg*. 2021;16(1):132. https://doi.org/10.1186/s13019-021-01513-y
102. Figueras J, Alcalde O, Barrabés JA, et al. Changes in hospital mortality rates in 425 patients with acute ST-elevation myocardial infarction and cardiac rupture over a 30-year period. *Circulation*. 2008;118(25):2783-2789. https://doi.org/10.1161/circulationaha.108.776690
103. López-Sendón J, Gurfinkel EP, Lopez de Sa E, et al. Factors related to heart rupture in acute coronary syndromes in the Global Registry of Acute Coronary Events. *Eur Heart J*. 2010;31(12):1449-1456. https://doi.org/10.1093/eurheartj/ehq061
104. Slater J, Brown RJ, Antonelli TA, et al. Cardiogenic shock due to cardiac free-wall rupture or tamponade after acute myocardial infarction: a report from the SHOCK trial registry. Should we emergently revascularize occluded coronaries for cardiogenic shock? *J Am Coll Cardiol*. 2000;36(3 Suppl A):1117-1122. https://doi.org/10.1016/s0735-1097(00)00845-7
105. Matteucci M, Fina D, Jiritano F, et al. Treatment strategies for post-infarction left ventricular free-wall rupture. *Eur Heart J Acute Cardiovasc Care*. 2019;8(4):379-387. https://doi.org/10.1177/2048872619840876
106. Matteucci M, Formica F, Kowalewski M, et al. Meta-analysis of surgical treatment for postinfarction left ventricular free-wall rupture. *J Card Surg*. 2021;36(9):3326-3333. https://doi.org/10.1111/jocs.15701
107. Frances C, Romero A, Grady D. Left ventricular pseudoaneurysm. *J Am Coll Cardiol*. 1998;32(3):557-561. https://doi.org/10.1016/s0735-1097(98)00290-3
108. Hung MJ, Cherng WJ, Kuo LT, Wang CH. Echocardiographic characteristics of patients surviving nonsurgically treated left ventricular pseudoaneurysm after acute myocardial infarction. *Am J Cardiol*. 2003;91(3):328-331. https://doi.org/10.1016/s0002-9149(02)03161-2
109. Yeo TC, Malouf JF, Oh JK, Seward JB. Clinical profile and outcome in 52 patients with cardiac pseudoaneurysm. *Ann Intern Med*. 1998;128(4):299-305. https://doi.org/10.7326/0003-4819-128-4-199802150-00010
110. López-Sendón J, González A, López de Sá E, et al. Diagnosis of subacute ventricular wall rupture after acute myocardial infarction: sensitivity and specificity of clinical, hemodynamic and echocardiographic criteria. *J Am Coll Cardiol*. 1992;19(6):1145-1153. https://doi.org/10.1016/0735-1097(92)90315-e
111. Nappi G, De Santo LS, Torella M, et al. Treatment strategies for postinfarction left ventricular free wall rupture: stabilization with peri-operative IABP and off-pump repair. *Int J Artif Organs*. 2003;26(4):346-350. https://doi.org/10.1177/039139880302600410
112. Johnston N, Wells CW, Samuels TL, Blumin JH. Rationale for targeting pepsin in the treatment of reflux disease. *Ann Otol Rhinol Laryngol*. 2010;119(8):547-558. https://doi.org/10.1177/000348941011900808
113. Iemura J, Oku H, Otaki M, Kitayama H, Inoue T, Kaneda T. Surgical strategy for left ventricular free wall rupture after acute myocardial infarction. *Ann Thorac Surg*. 2001;71(1):201-204. https://doi.org/10.1016/s0003-4975(00)02211-6
114. Okada K, Yamashita T, Matsumori M, et al. Surgical treatment for rupture of left ventricular free wall after acute myocardial infarction. *Interact Cardiovasc Thorac Surg*. 2005;4(3):203-206. https://doi.org/10.1510/icvts.2004.100321
115. Hochman JS, Sleeper LA, Webb JG, et al. Early revascularization in acute myocardial infarction complicated by cardiogenic shock. SHOCK Investigators. Should we emergently revascularize occluded coronaries for cardiogenic shock. *N Engl J Med*. 1999;341(9):625-634. https://doi.org/10.1056/nejm199908263410901
116. Cuenca-Barrales C, Montero-Vílchez T, Szepietowski JC, Matusiak L, Molina-Leyva A. Sexual impairment in patients with hidradenitis suppurativa: a systematic review. *J Eur Acad Dermatol Venereol*. 2021;35(2):345-352. https://doi.org/10.1111/jdv.16726
117. Ramzy D, Anderson M, Batsides G, et al. Early outcomes of the first 200 US patients treated with Impella 5.5: a novel temporary left ventricular assist device. *Innovations (Phila)*. 2021;16(4):365-372. https://doi.org/10.1177/15569845211013329
118. Kennel PJ, Lumish H, Kaku Y, et al. A case series analysis on the clinical experience of Impella 5.5® at a large tertiary care centre. *ESC Heart Fail*. 2021;8(5):3720-3725. https://doi.org/10.1002/ehf2.13512
119. Elsokkari I, Sapp JL. Electrical storm: prognosis and management. *Prog Cardiovasc Dis*. 2021;66:70-79. https://doi.org/10.1016/j.pcad.2021.06.007
120. Chen CY, Tsai J, Hsu TY, et al. ECMO Used in a refractory ventricular tachycardia and ventricular fibrillation patient: a national case-control study. *Medicine (Baltimore)*. 2016;95(13):e3204. https://doi.org/10.1097/md.0000000000003204
121. Rao P, Khalpey Z, Smith R, Burkhoff D, Kociol RD. Venoarterial extracorporeal membrane oxygenation for cardiogenic shock and cardiac arrest. *Circ Heart Fail*. 2018;11(9):e004905. https://doi.org/10.1161/circheartfailure.118.004905
122. Caminiti R, Colarusso L, Vizzari G, Crea P. Tolerance of sustained ventricular fibrillation during left ventricular assist device support with IMPELLA CP®. *Cardiovasc Revasc Med*. 2022;40s:305-307. https://doi.org/10.1016/j.carrev.2021.11.044
123. Fiorelli F, Panoulas V. Impella as unloading strategy during VA-ECMO: systematic review and meta-analysis. *Rev Cardiovasc Med*. 2021;22(4):1503-1511. https://doi.org/10.31083/j.rcm2204154
124. Lüsebrink E, Binzenhöfer L, Kellnar A, et al. Venting during venoarterial extracorporeal membrane oxygenation. *Clin Res Cardiol*. 2023;112(4):464-505. https://doi.org/10.1007/s00392-022-02069-0
125. Condello I. Minimal invasive extracorporeal circulation an alternative to ECMO in ventricular tachycardia ablation. *J Extra Corpor Technol*. 2023;55(3):138-143. https://doi.org/10.1051/ject/2023031

ADULT

126. Palaniswamy C, Miller MA, Reddy VY, Dukkipati SR. Hemodynamic support for ventricular tachycardia ablation. *Card Electrophysiol Clin*. 2017;9(1):141-152. https://doi.org/10.1016/j.ccep.2016.10.011
127. Weiss JN, Nademanee K, Stevenson WG, Singh B. Ventricular arrhythmias in ischemic heart disease. *Ann Intern Med*. 1991;114(9):784-797. https://doi.org/10.7326/0003-4819-114-9-784
128. Khanal RR, Gajurel RM, Shah S, et al. Arrhythmias: its occurrence, risk factors, therapy, and prognosis in acute coronary syndrome. *J Nepal Health Res Counc*. 2023;21(1):8-14. https://doi.org/10.33314/jnhrc.v21i1.4019
129. Norawat R, Maybauer MO, O'Keeffe N, Vohra A. Extracorporeal membrane oxygenation for protected catheter ablation in a post-cardiotomy patient with electrical storm. *Ann Card Anaesth*. 2024;27(3):256-259. https://doi.org/10.4103/aca.aca_180_23
130. Sroubek J, Vajapey R, Sipko JJ, et al. First-in-human experience with Impella 5.0/5.5 for high-risk patients with advanced heart failure undergoing VT ablation. *J Am Coll Cardiol*. 2023;82(5):469-471. https://doi.org/10.1016/j.jacc.2023.05.012
131. Ko WJ, Lin CY, Chen RJ, Wang SS, Lin FY, Chen YS. Extracorporeal membrane oxygenation support for adult postcardiotomy cardiogenic shock. *Ann Thorac Surg*. 2002;73(2):538-545. https://doi.org/10.1016/s0003-4975(01)03330-6
132. Chen RJ, Ko WJ, Lin FY. Successful rescue of sustained ventricular tachycardia/ventricular fibrillation after coronary artery bypass grafting by extracorporeal membrane oxygenation. *J Formos Med Assoc*. 2002;101(4):283-286.
133. Hong Y, Agrawal N, Hess NR, et al. Outcomes of Impella 5.0 and 5.5 for cardiogenic shock: a single-center 137 patient experience. *Artif Organs*. 2024;48(7):771-780. https://doi.org/10.1111/aor.14735
134. Bunge JJH, Mariani S, Meuwese C, et al. Characteristics and outcomes of prolonged venoarterial extracorporeal membrane oxygenation after cardiac surgery: the Post-Cardiotomy Extracorporeal Life Support (PELS-1) cohort study. *Crit Care Med*. 2024;52(10):e490-e502. https://doi.org/10.1097/ccm.0000000000006349
135. Enriquez A, Liang J, Gentile J, et al. Outcomes of rescue cardiopulmonary support for periprocedural acute hemodynamic decompensation in patients undergoing catheter ablation of electrical storm. *Heart Rhythm*. 2018;15(1):75-80. https://doi.org/10.1016/j.hrthm.2017.09.005
136. Yue HY, Peng W, Luo K, et al. Impact of awake extracorporeal membrane oxygenation on patients mortality with cardiogenic shock: a systematic review and trial sequential meta-analysis based on observational studies. *BMJ Open*. 2024;14(10):e086383. https://doi.org/10.1136/bmjopen-2024-086383
137. Ezad SM, Ryan M, Donker DW, et al. Unloading the left ventricle in venoarterial ECMO: in whom, when, and how? *Circulation*. 2023;147(16):1237-1250. https://doi.org/10.1161/circulationaha.122.062371
138. Privratsky JR, Diaz S, Nicoara A, Daneshmand MA. In reply to: "Intra-aortic balloon pump protects against hydrostatic pulmonary oedema during peripheral venoarterial-extracorporeal membrane oxygenation". *Eur Heart J Acute Cardiovasc Care*. 2021;10(1):81-82. https://doi.org/10.1177/2048872618779772
139. Gandhi KD, Moras EC, Niroula S, et al. Left ventricular unloading with Impella versus IABP in patients with VA-ECMO: a systematic review and meta-analysis. *Am J Cardiol*. 2023;208:53-59. https://doi.org/10.1016/j.amjcard.2023.09.023
140. Piperata A, Van den Eynde J, David CH, et al. ECMO alone versus ECPELLA in patients affected by cardiogenic shock: the multicenter EVACS study. *ASAIO J*. 2024;70(11):946-953. https://doi.org/10.1097/mat.0000000000002219
141. Kayali F, Tahhan O, Vecchio G, et al. Left ventricular unloading to facilitate ventricular remodelling in heart failure: a narrative review of mechanical circulatory support. *Exp Physiol*. 2024;109(11):1826-1836. https://doi.org/10.1113/ep091796
142. Cevasco M, Takayama H, Ando M, Garan AR, Naka Y, Takeda K. Left ventricular distension and venting strategies for patients on venoarterial extracorporeal membrane oxygenation. *J Thorac Dis*. 2019;11(4):1676-1683. https://doi.org/10.21037/jtd.2019.03.29
143. Keenan JE, Schechter MA, Bonadonna DK, et al. Early experience with a novel cannulation strategy for left ventricular decompression during nonpostcardiotomy venoarterial ECMO. *ASAIO J*. 2016;62(3):e30-e34. https://doi.org/10.1097/mat.0000000000000333
144. Perry T, Greenberg JW, Cooper DS, et al. Balloon atrial septostomy versus left atrial cannulation for left heart decompression in children with dilated cardiomyopathy and myocarditis on extracorporeal membrane oxygenation: an ELSO registry analysis. *Perfusion*. 2024;39(8):1732-1739. https://doi.org/10.1177/02676591231220816
145. Shi J, Levett JY, Lv H, et al. Surgical repair of post myocardial infarction ventricular septal defect: a retrospective analysis of a single institution experience. *J Cardiothorac Surg*. 2023;18(1):313. https://doi.org/10.1186/s13019-023-02418-8
146. Jones BM, Kapadia SR, Smedira NG, et al. Ventricular septal rupture complicating acute myocardial infarction: a contemporary review. *Eur Heart J*. 2014;35(31):2060-2068. https://doi.org/10.1093/eurheartj/ehu248
147. Hajjar LA, Teboul JL. Mechanical circulatory support devices for cardiogenic shock: state of the art. *Crit Care*. 2019;23(1):76. https://doi.org/10.1186/s13054-019-2368-y
148. Perez-Villa B, Cubeddu RJ, Brozzi N, Sleiman JR, Navia J, Hernandez-Montfort J. Transition to heart transplantation in post-myocardial infarction ventricular septal rupture: a systematic review. *Heart Fail Rev*. 2023;28(1):217-227. https://doi.org/10.1007/s10741-021-10161-2
149. Fernandez Valledor A, Rubinstein G, Moeller CM, et al. "Durable left ventricular assist devices as a bridge to transplantation in The Old and The New World". *J Heart Lung Transplant*. 2024;43(6):1010-1020. https://doi.org/10.1016/j.healun.2024.01.019
150. Faber C, McCarthy PM, Smedira NG, Young JB, Starling RC, Hoercher KJ. Implantable left ventricular assist device for patients with postinfarction ventricular septal defect. *J Thorac Cardiovasc Surg*. 2002;124(2):400-401. https://doi.org/10.1067/mtc.2002.124243
151. Kshettry VR, Salerno CT, Bank AJ. Risk of left ventricular assist device as a bridge to heart transplant following postinfarction ventricular septal rupture. *J Card Surg*. 1997;12(2):93-97. https://doi.org/10.1111/j.1540-8191.1997.tb00101.x
152. Hlaváček D, Pokorný M, Ivák P, Netuka I, Szárszoi O. Implantation of durable left ventricular assist device in patient with postmyocardial infarction ventricular septal defect. *J Card Surg*. 2021;36(10):3944-3947. https://doi.org/10.1111/jocs.15839
153. Ton VK, Garan AR, Takeda K, Takayama H, Naka Y. LVAD implantation following repair of acute postmyocardial infarction ventricular septal defect. *J Card Surg*. 2016;31(10):658-659. https://doi.org/10.1111/jocs.12781
154. Kawanami S, Egami Y, Nishino M, Tanouchi J. One-week Impella CP support for papillary muscle rupture as a bridge to surgery: a case report. *Eur Heart J Case Rep*. 2023;7(7):ytad274. https://doi.org/10.1093/ehjcr/ytad274
155. Saito S, Shibasaki I, Matsuoka T, et al. Impella support as a bridge to heart surgery in patients with cardiogenic shock. *Interact Cardiovasc Thorac Surg*. 2022;35(2). https://doi.org/10.1093/icvts/ivac088
156. Radakovic D, Penov K, Güder G, Aleksic I. Left ventricular assist device implantation in a patient with ventricular pseudoaneurysm. *Thorac Cardiovasc Surg Rep*. 2022;11(1):e11-e13. https://doi.org/10.1055/s-0041-1741554
157. Kacer J, Lindovska M, Surovcik R, et al. Refractory cardiogenic shock due to extensive anterior STEMI with covered left ventricular free wall rupture treated with awake VA-ECMO and LVAD as a double bridge to heart transplantation - collaboration of three cardiac centres. *Biomed Pap Med Fac Univ Palacky Olomouc Czech Repub*. 2015;159(4):681-687. https://doi.org/10.5507/bp.2015.044
158. Gregoric ID. Total artificial heart in patients with post-infarction ventricular septal defect. *Ann Cardiothorac Surg*. 2020;9(2):116-117. https://doi.org/10.21037/acs.2020.01.04
159. Arabía FA, Cantor RS, Koehl DA, et al. Interagency registry for mechanically assisted circulatory support report on the total artificial heart. *J Heart Lung Transplant*. 2018;37(11):1304-1312. https://doi.org/10.1016/j.healun.2018.04.004
160. Copeland JG, Smith RG, Arabia FA, et al. Cardiac replacement with a total artificial heart as a bridge to transplantation. *N Engl J Med*. 2004;351(9):859-867. https://doi.org/10.1056/NEJMoa040186
161. Carrier M, Moriguchi J, Shah KB, et al. Outcomes after heart transplantation and total artificial heart implantation: a multicenter study. *J Heart Lung Transplant*. 2021;40(3):220-228. https://doi.org/10.1016/j.healun.2020.11.012
162. O'Gara PT, Kushner FG, Ascheim DD, et al. 2013 ACCF/AHA guideline for the management of ST-elevation myocardial infarction: a report of the American College of Cardiology Foundation/American Heart Association Task Force on Practice Guidelines. *Circulation*. 2013;127(4):e362-e425. https://doi.org/10.1161/CIR.0b013e3182742cf6
163. Batchelor WB, Anwaruddin S, Wang DD, et al. The multidisciplinary heart team in cardiovascular medicine: current role and future challenges. *JACC Adv*. 2023;2(1):100160. https://doi.org/10.1016/j.jacadv.2022.100160

ADULT

164. Burzotta F, Graziani F, Trani C, et al. Clinical impact of heart team decisions for patients with complex valvular heart disease: a large, single-center experience. *J Am Heart Assoc*. 2022;11(11):e024404. https://doi.org/10.1161/jaha.121.024404
165. Tsang MB, Schwalm JD, Gandhi S, et al. Comparison of heart team vs interventional cardiologist recommendations for the treatment of patients with multivessel coronary artery disease. *JAMA Netw Open*. 2020;3(8):e2012749. https://doi.org/10.1001/jamanetworkopen.2020.12749
166. Head SJ, Kaul S, Mack MJ, et al. The rationale for Heart Team decision-making for patients with stable, complex coronary artery disease. *Eur Heart J*. 2013;34(32):2510-2518. https://doi.org/10.1093/eurheartj/eht059
167. Hobohm L, Farmakis IT, Keller K, et al. Pulmonary embolism response team (PERT) implementation and its clinical value across countries: a scoping review and meta-analysis. *Clin Res Cardiol*. 2023;112(10):1351-1361. https://doi.org/10.1007/s00392-022-02077-0
168. Gardner TA, Fuher A, Longino A, et al. Reduced mortality associated with pulmonary embolism response team consultation for intermediate and high-risk pulmonary embolism: a retrospective cohort study. *Thromb J*. 2024;22(1):38. https://doi.org/10.1186/s12959-024-00605-8

Key Words: acute myocardial infarction, cardiogenic shock, mechanical circulatory support, papillary muscle rupture, postinfarction ventricular septal defect, free wall rupture, arrhythmia

ADULT